AV Node Dependent SVT:Substrates, Mechanisms, and Recognition

Ching-Tai Tai

Taipei Veterans General Hospital

National Yang-Ming University

AV Node Reentry

- Anatomy
- Physiology
- Anatomic-Physiologic Relation
- AV Nodal Reentrant Tachycardia
- Radiofrequency Catheter Ablation

Anatomy

Tawara's Original Description of AV Conduction System

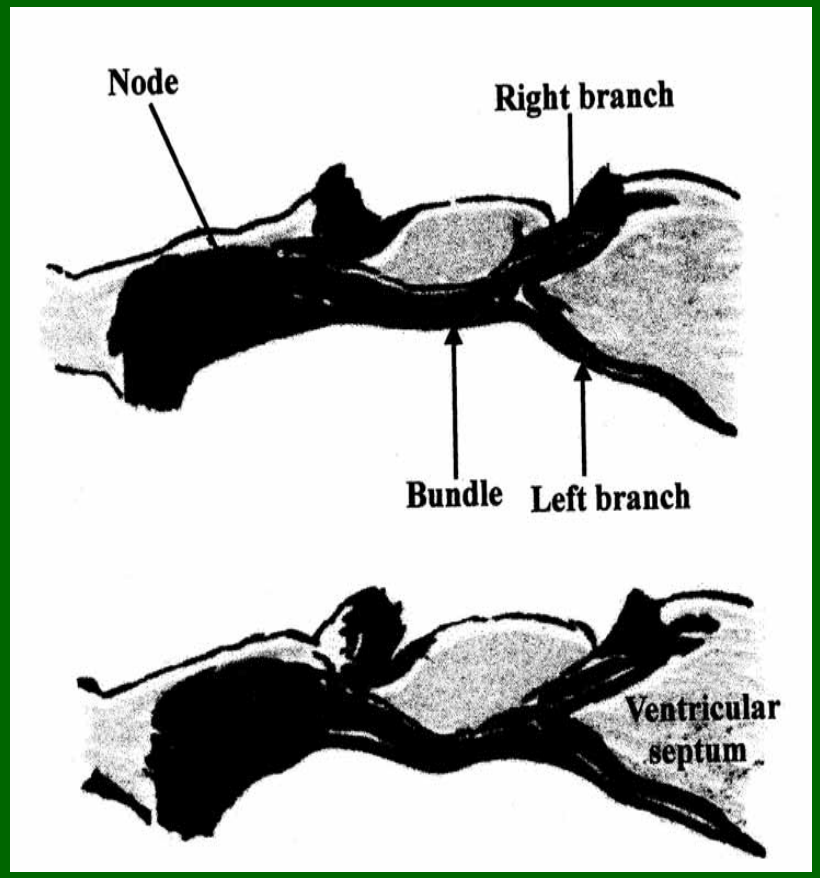

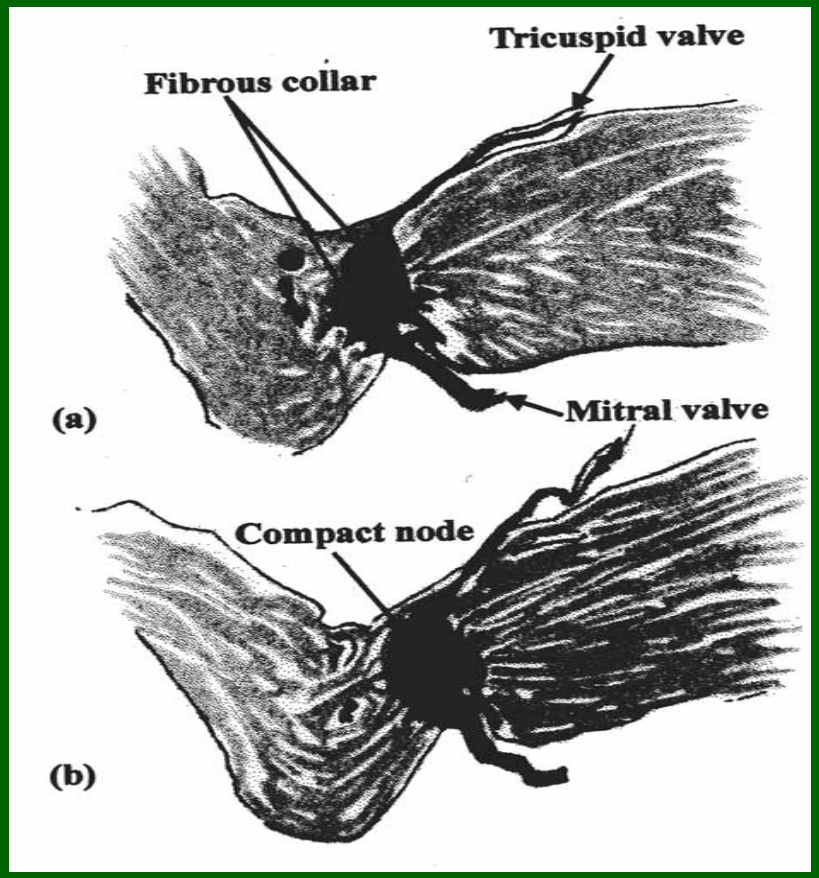

Jena:Gustav Fischer;1906

The Triangle of Koch

- Posterior boundary: tendon of Todaro
- Anterior boundary: septal leaflet of tricuspid valve
- Base: coronary sinus ostium and septal isthmus

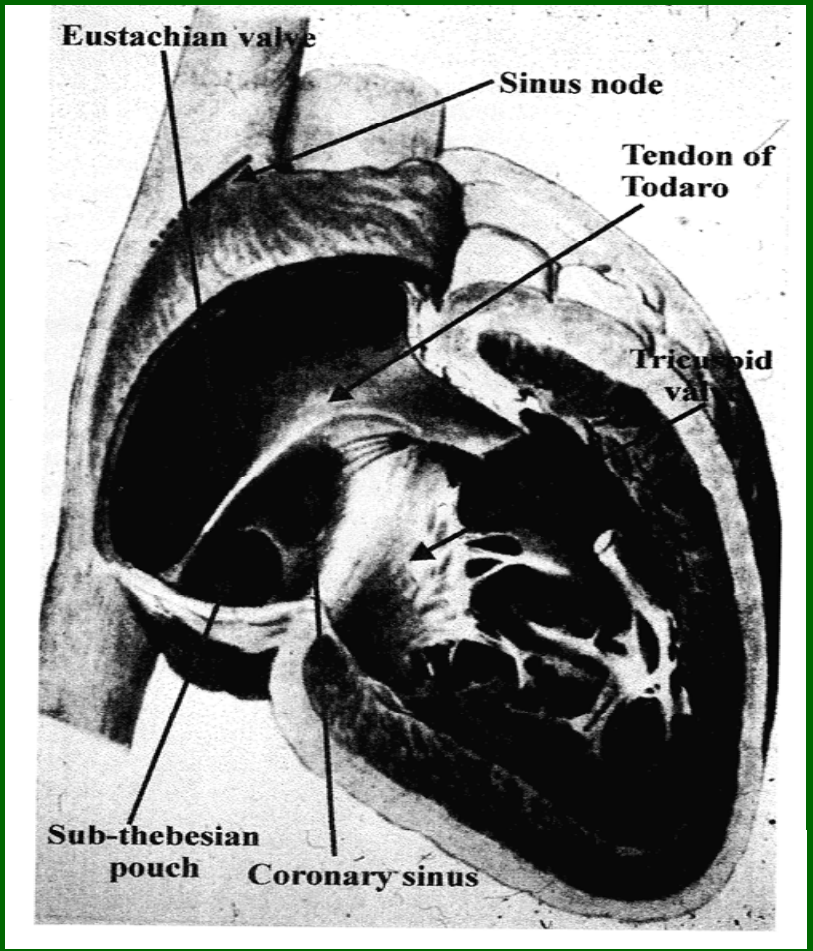

Verh Dtsch Pathol Ges 1909;13:909-920

Human AV Junctional Area

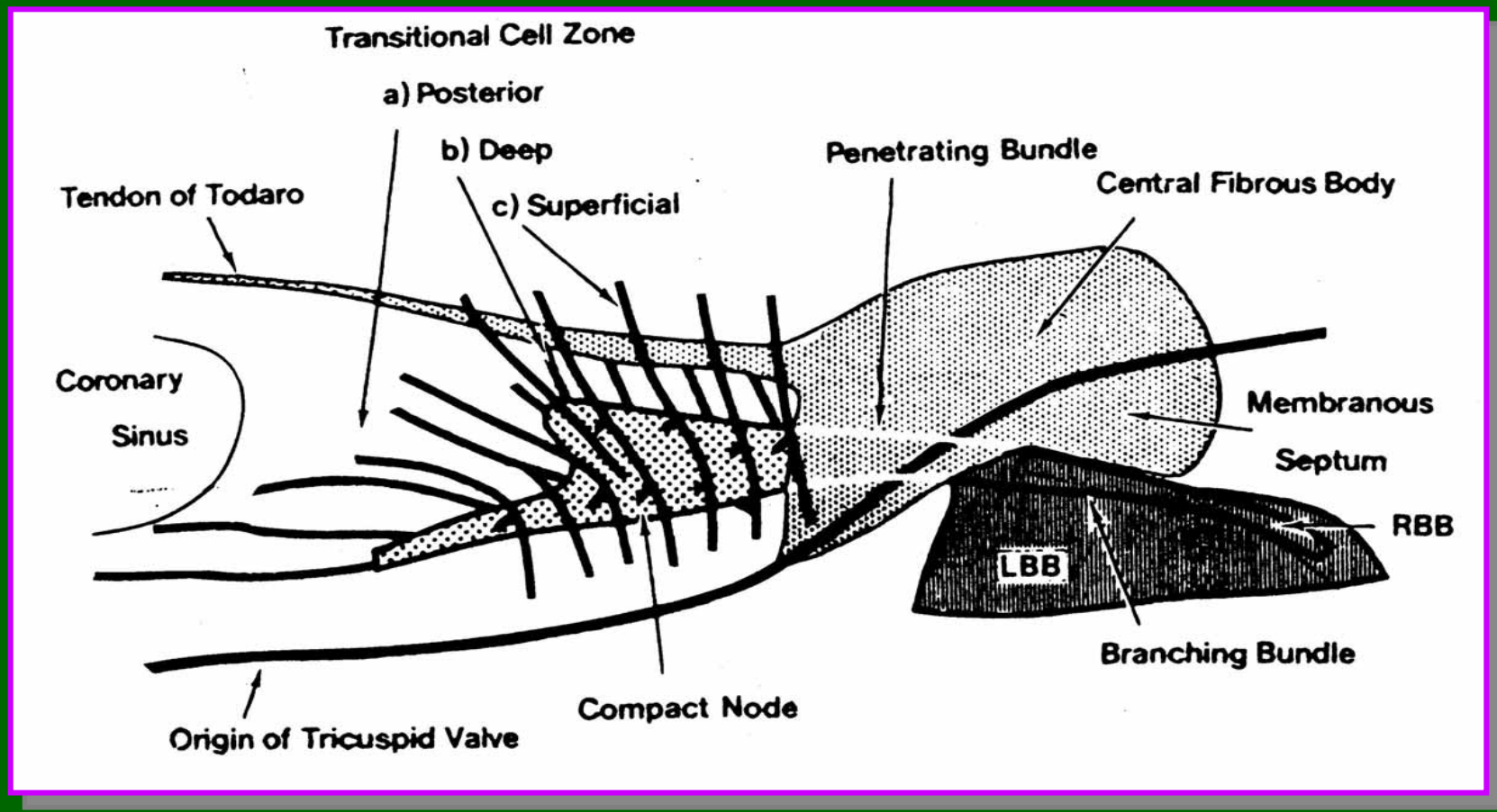

Becker and Anderson, 1976

Approaches to the AV Node

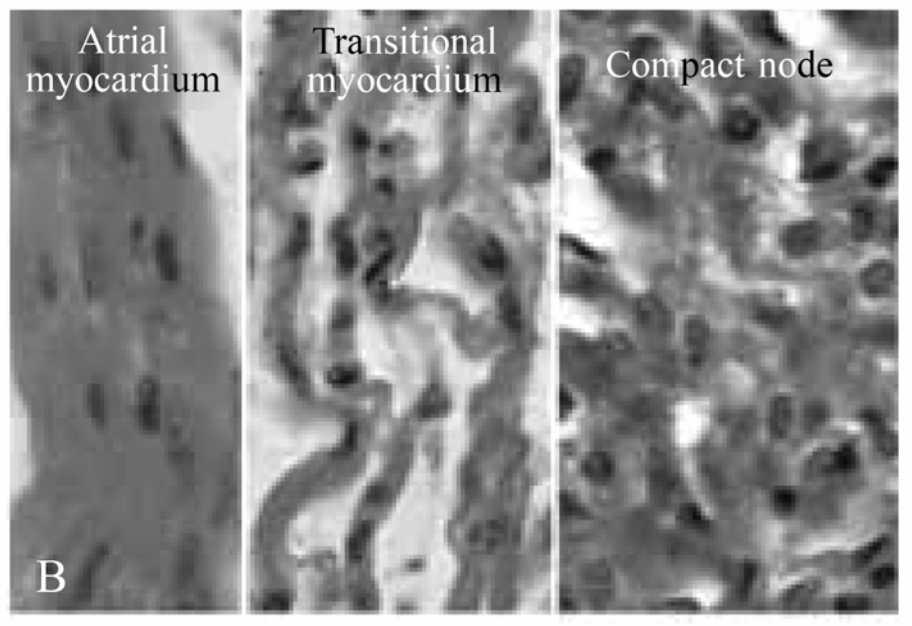

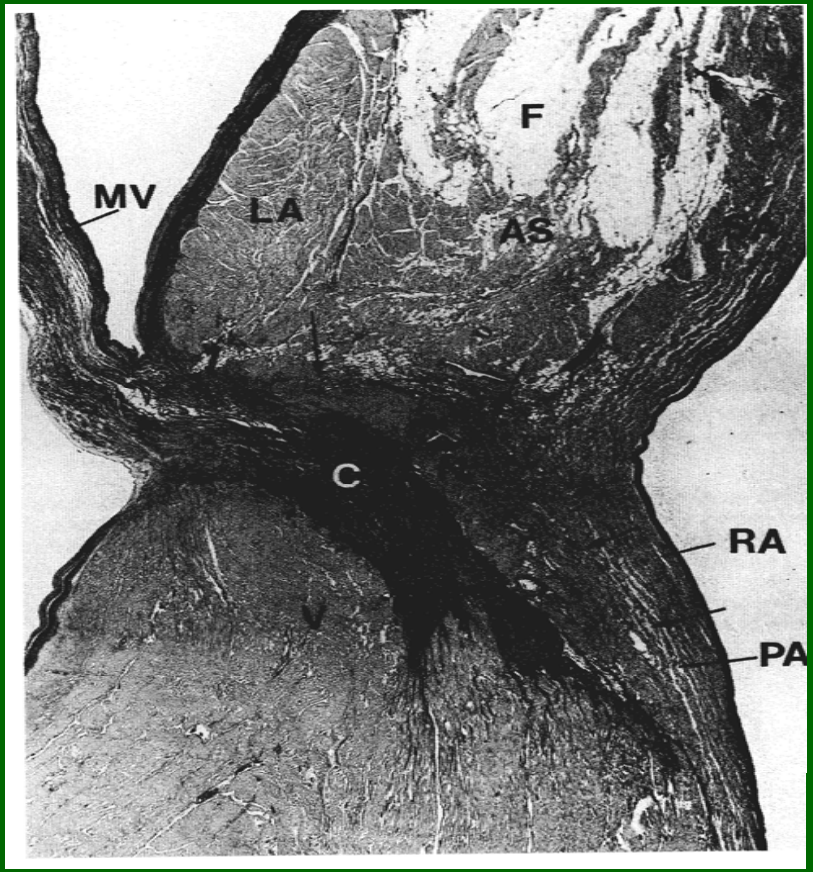

Bharati and Lev, 1984 and 1995

Compact AV Node

- Adult size: 5 to 7 mm in length, 2 to 5 mm in width
- Superficial layer (less nodal cells, more collagen, elastic tissue, and nerve fibers)
- Intermediate layer
- Deep layer (compact nodal cells, less collagen and elastic tissue)

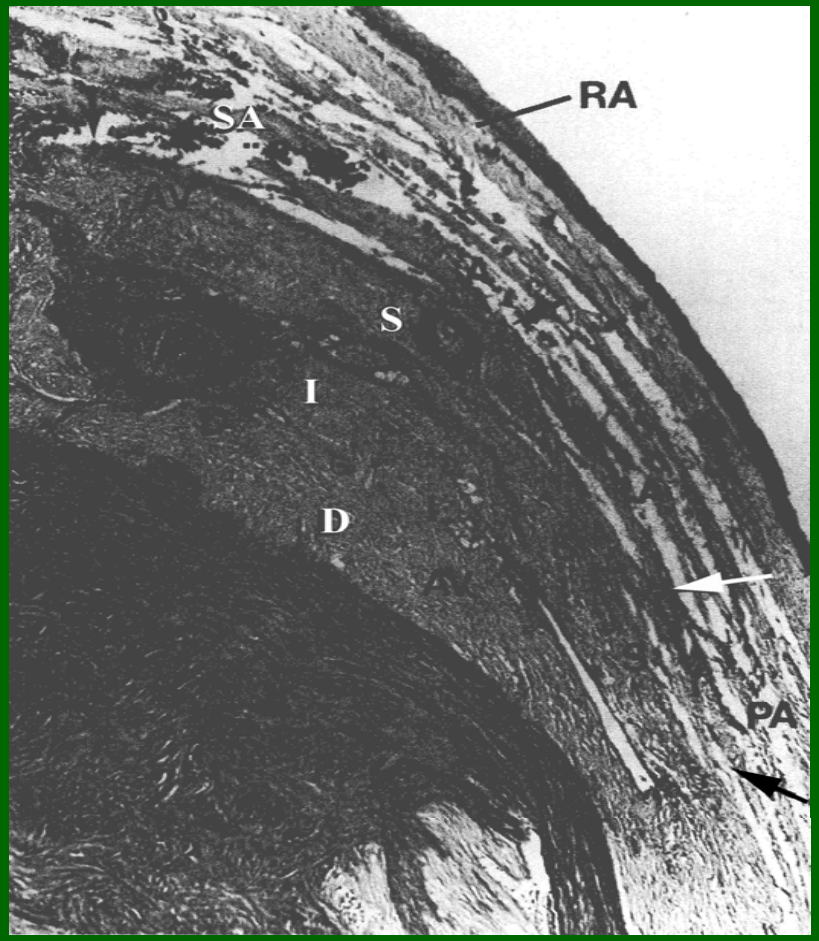

Bharati and Lev, 1995

Posterior Extensions of the Human Compact AVN

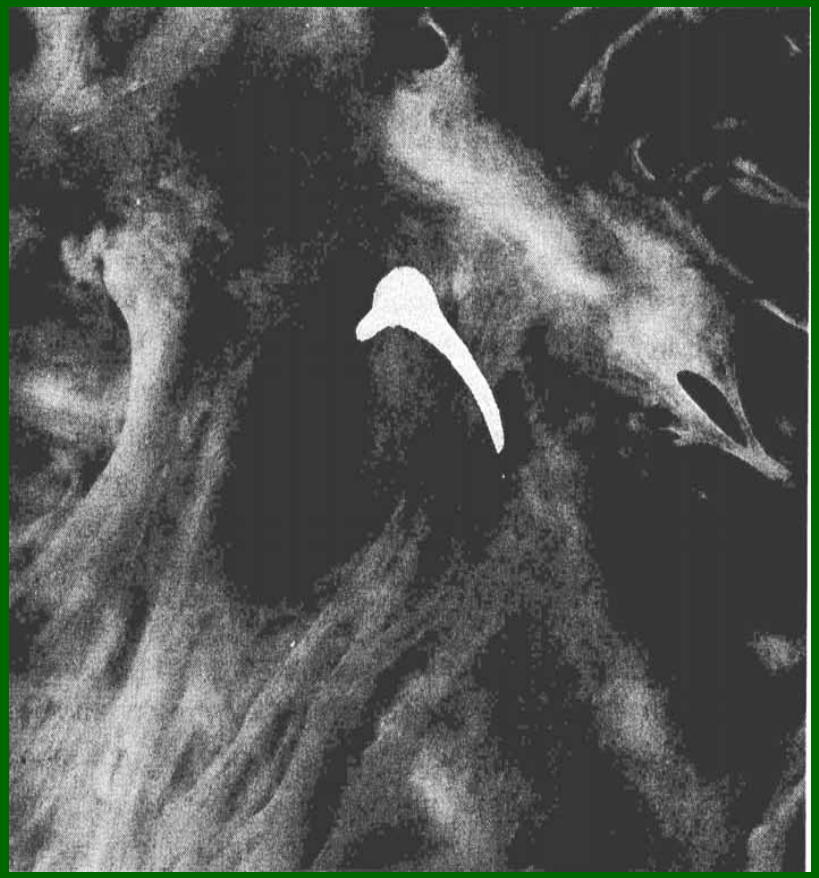

Inoue and Becker, Circulation 1998

Posterior Extensions of the Human Compact AVN

- The mean length of the right posterior extension was 4.4±2.0 mm
- The mean length of the left posterior extension was 1.8±0.9 mm

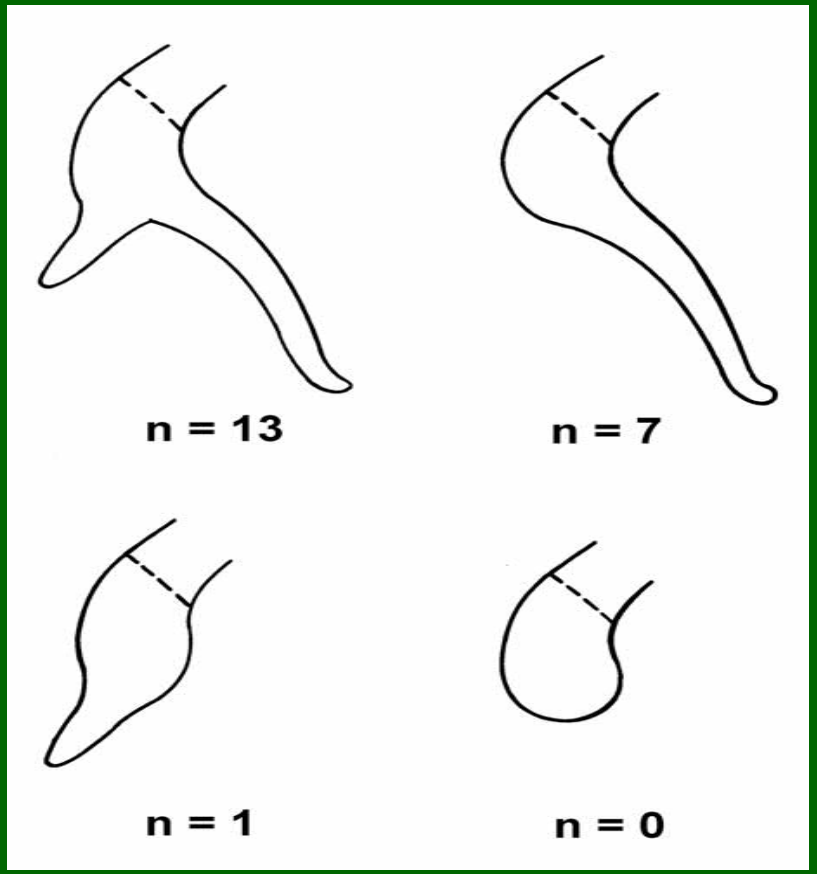

Inoue and Becker, Circulation 1998

Physiology

Cellular Electrophysiology

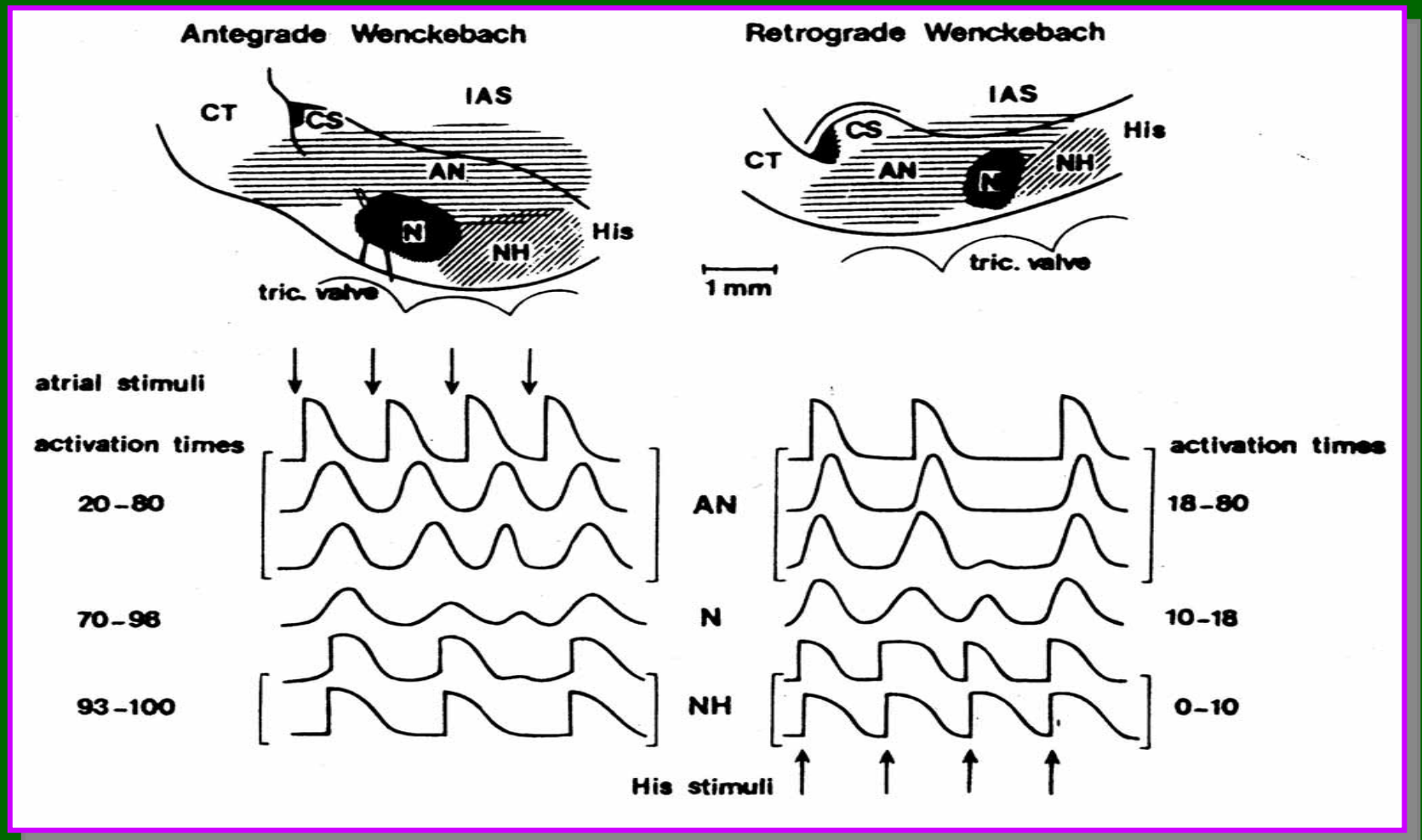

Janse et al, Circ Res 1969

Dual AV Nodal Pathway Physiology

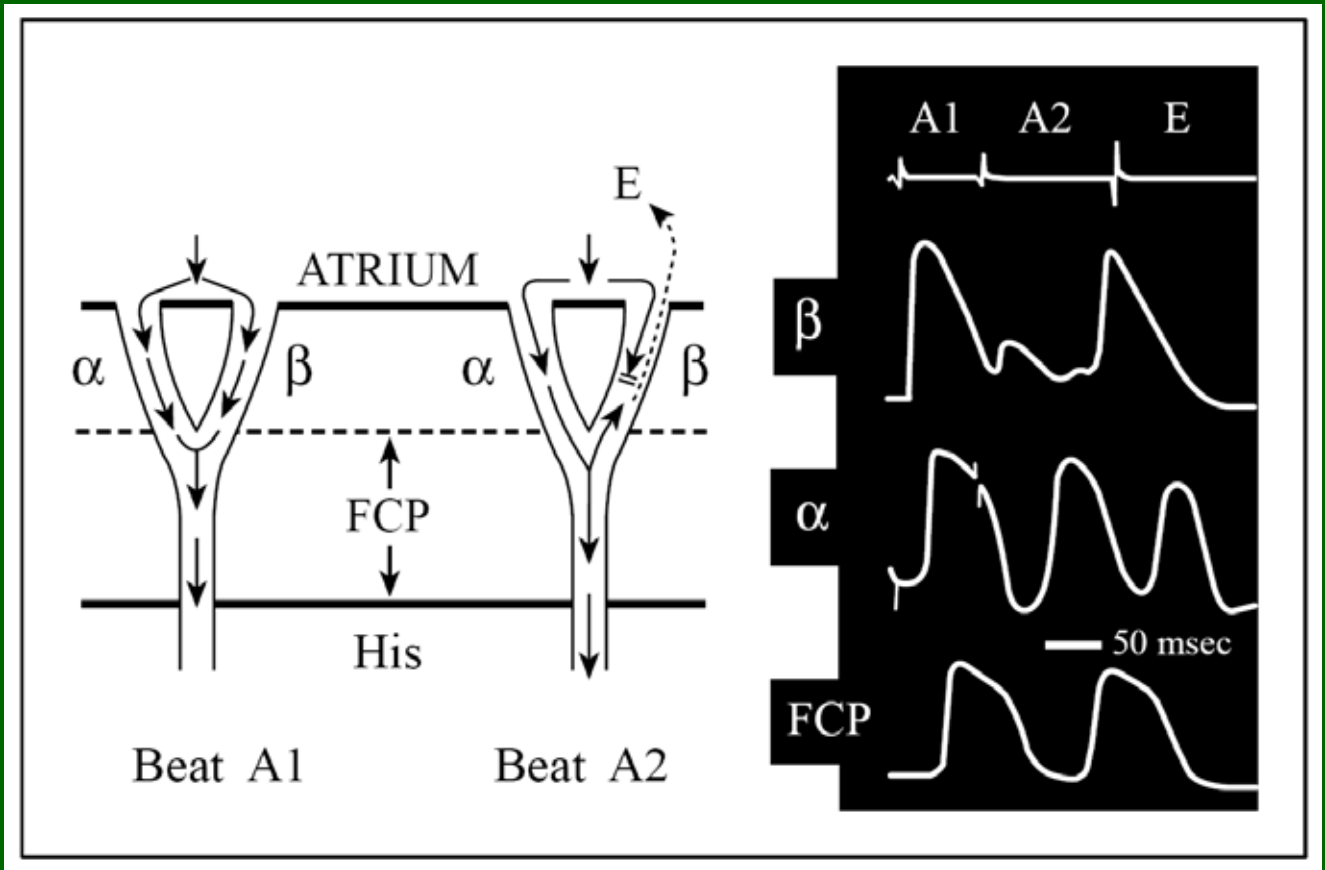

Mendez and Moe, Circ Res 1966

Optical Mapping of AV Node

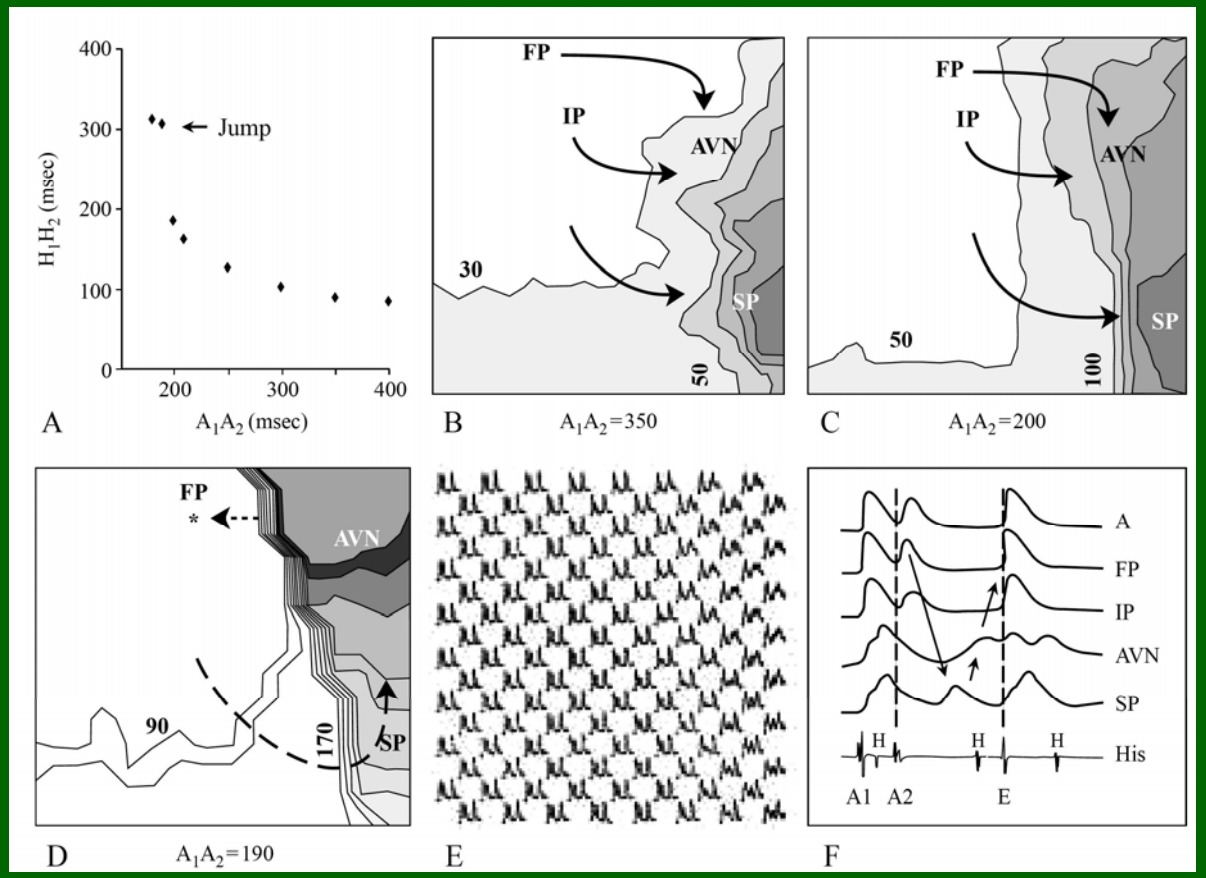

Wu J et al, Circ Res 2001

Human Antegrade Dual AV Nodal Pathways

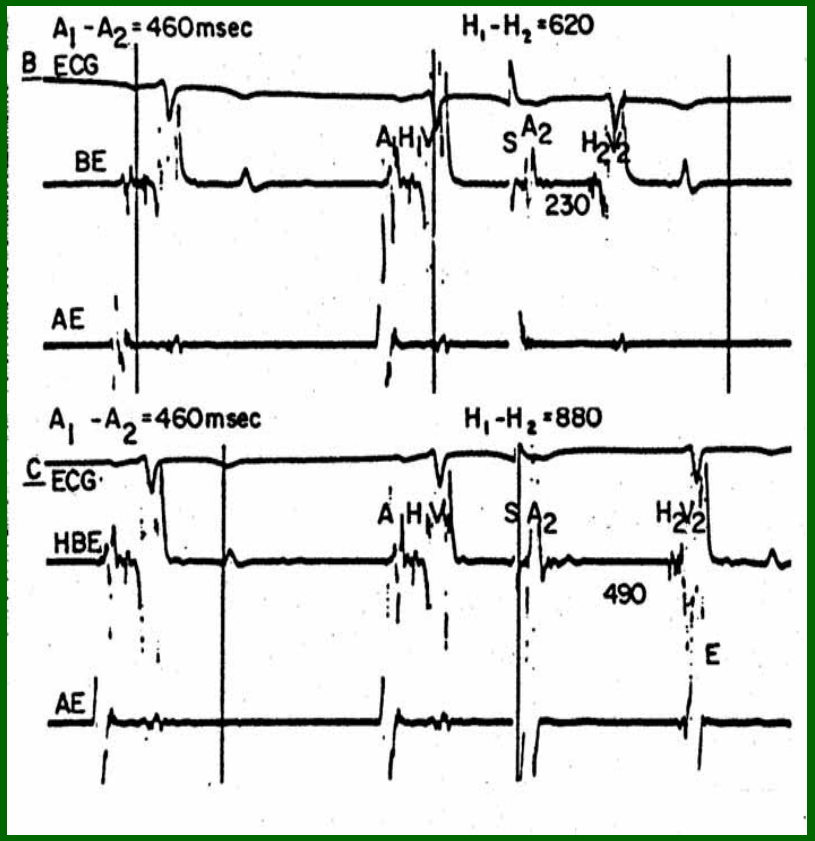

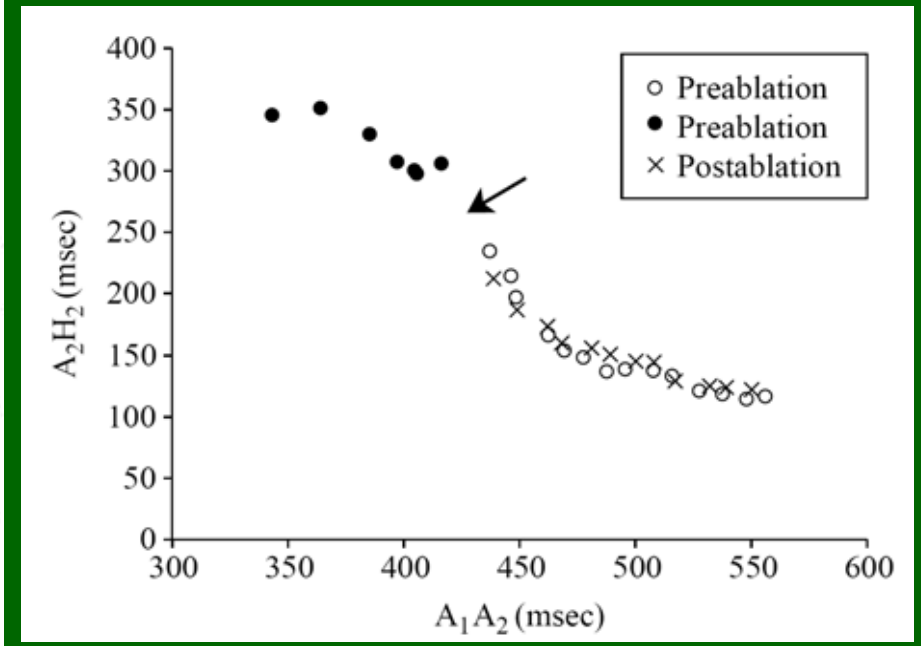

Denes and Rosen, Circulation 1973

Continuous Curves

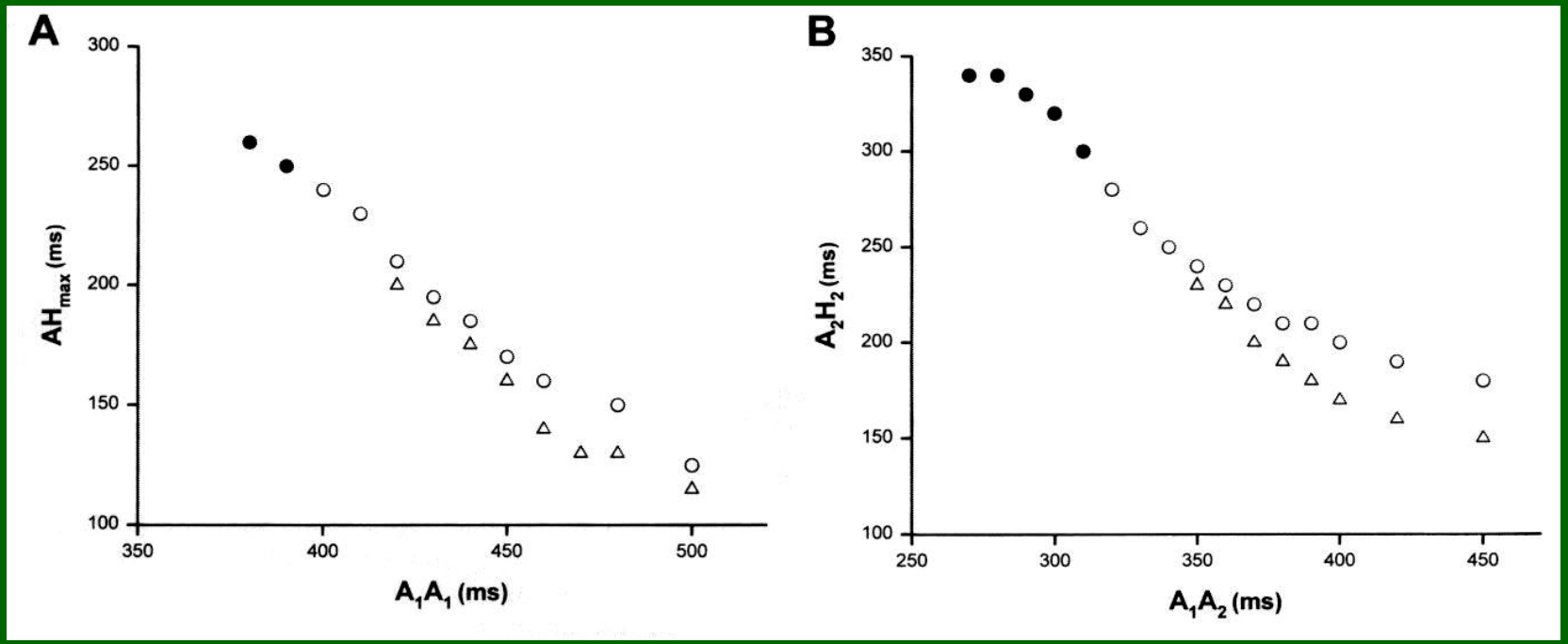

Tai et al, Circulation 1997

Human Retrograde Dual AV Nodal Pathways

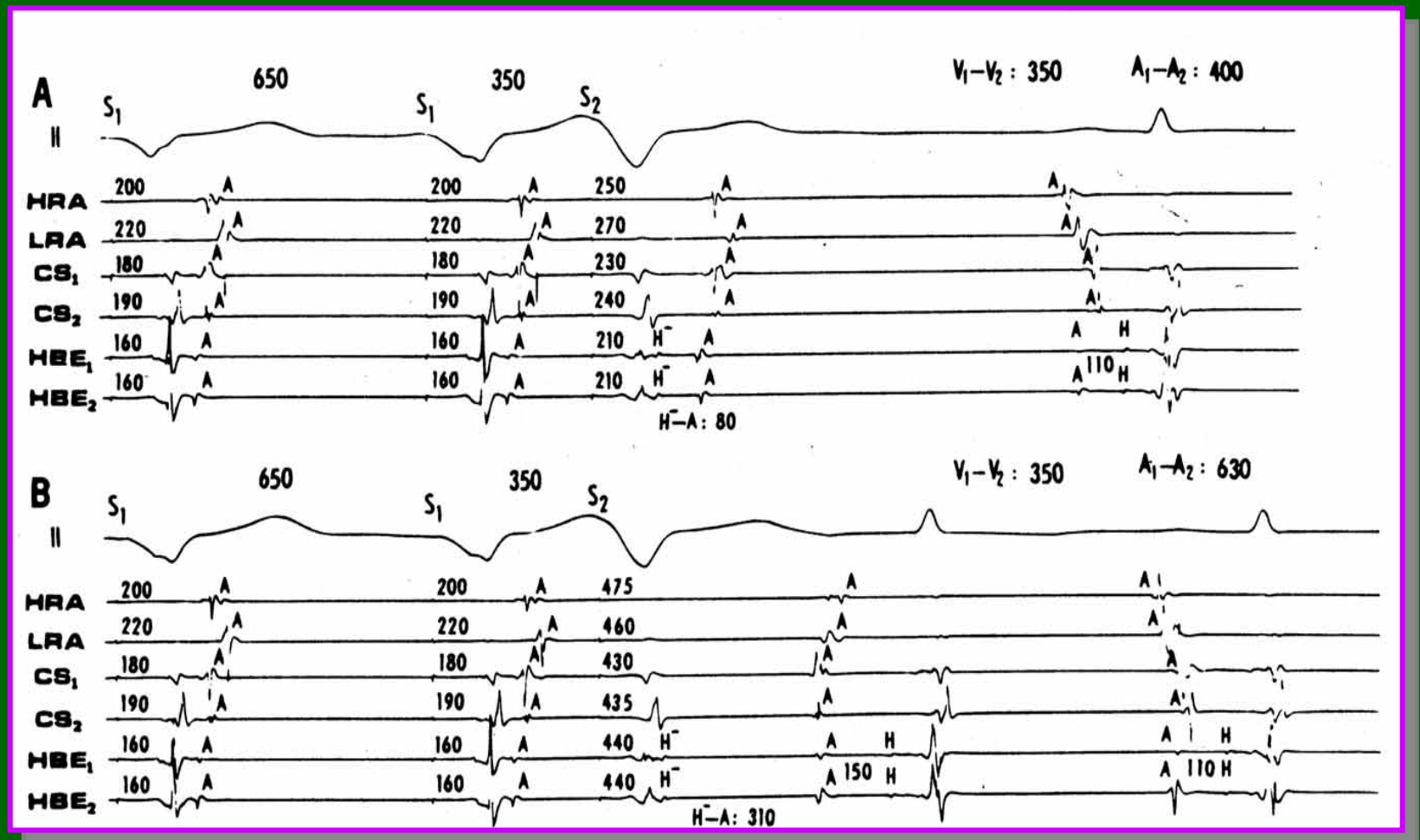

Sung RJ, Circulation 1981

Multiple AV Nodal Pathways

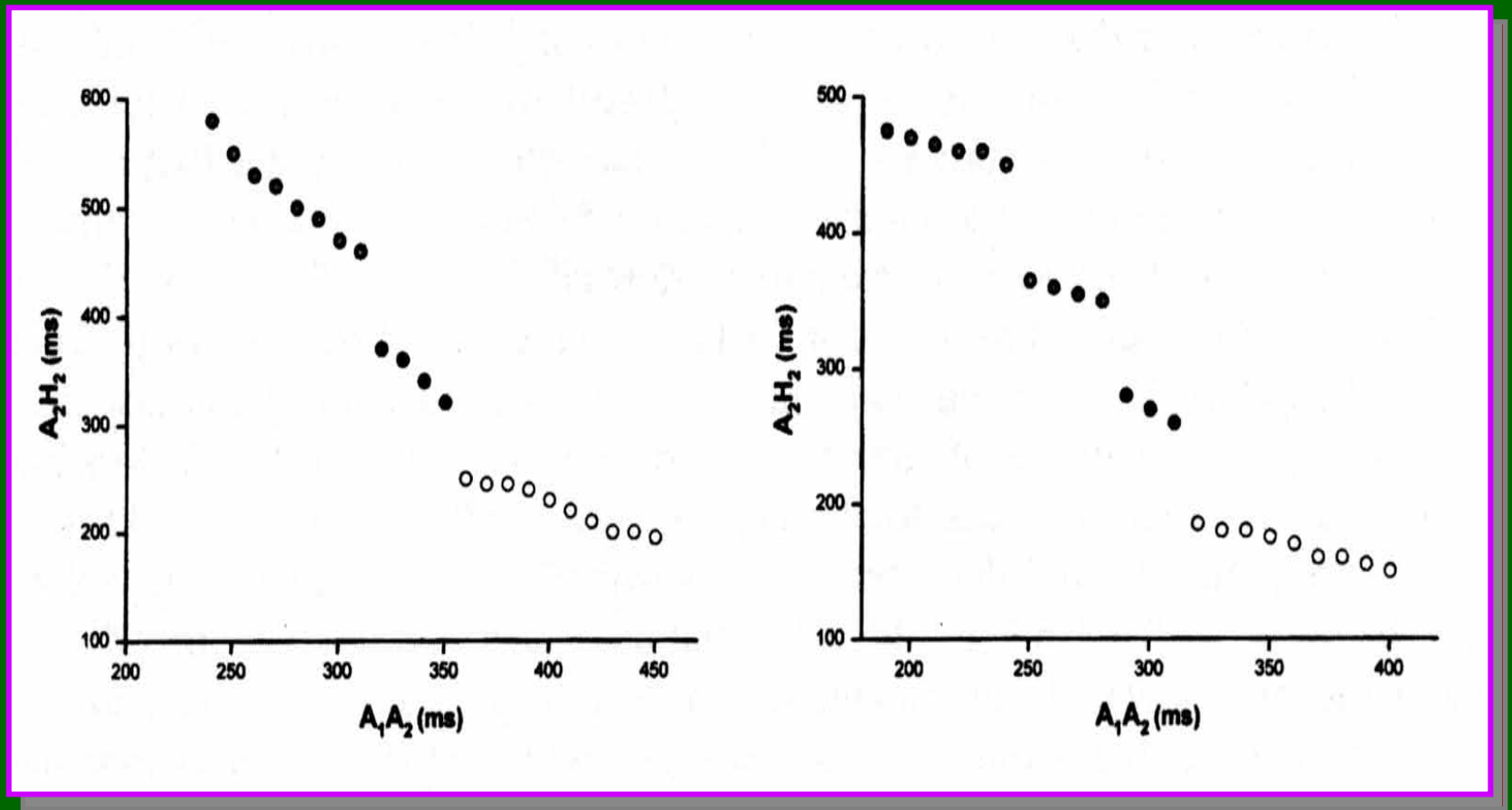

Tai CT, JACC 1996

Human AV Nodal Pathways

- Antegrade dual pathways
  - 50% to 90% of patients with AVNRT
  - 5% to 10% of patients without AVNRT
- Retrograde dual pathways
  - 8.5% to 41% of patients with AVNRT
- Antegrade multiple pathways
  - 5.2% of patients with AVNRT
- Retrograde multiple pathways
  - 2% of patients with AVNRT

ECG Manifestations of Dual AV Nodal Conduction

- Spontaneous prolongation of the PR interval
- Abrupt prolongation and normalization of the PR interval due to an APC and AT
- PR prolongation initiated by a VPC and terminated by reentry or an APC
- Simultaneous conduction along the fast and slow pathways

ECG Manifestations of Dual AV Nodal Conduction

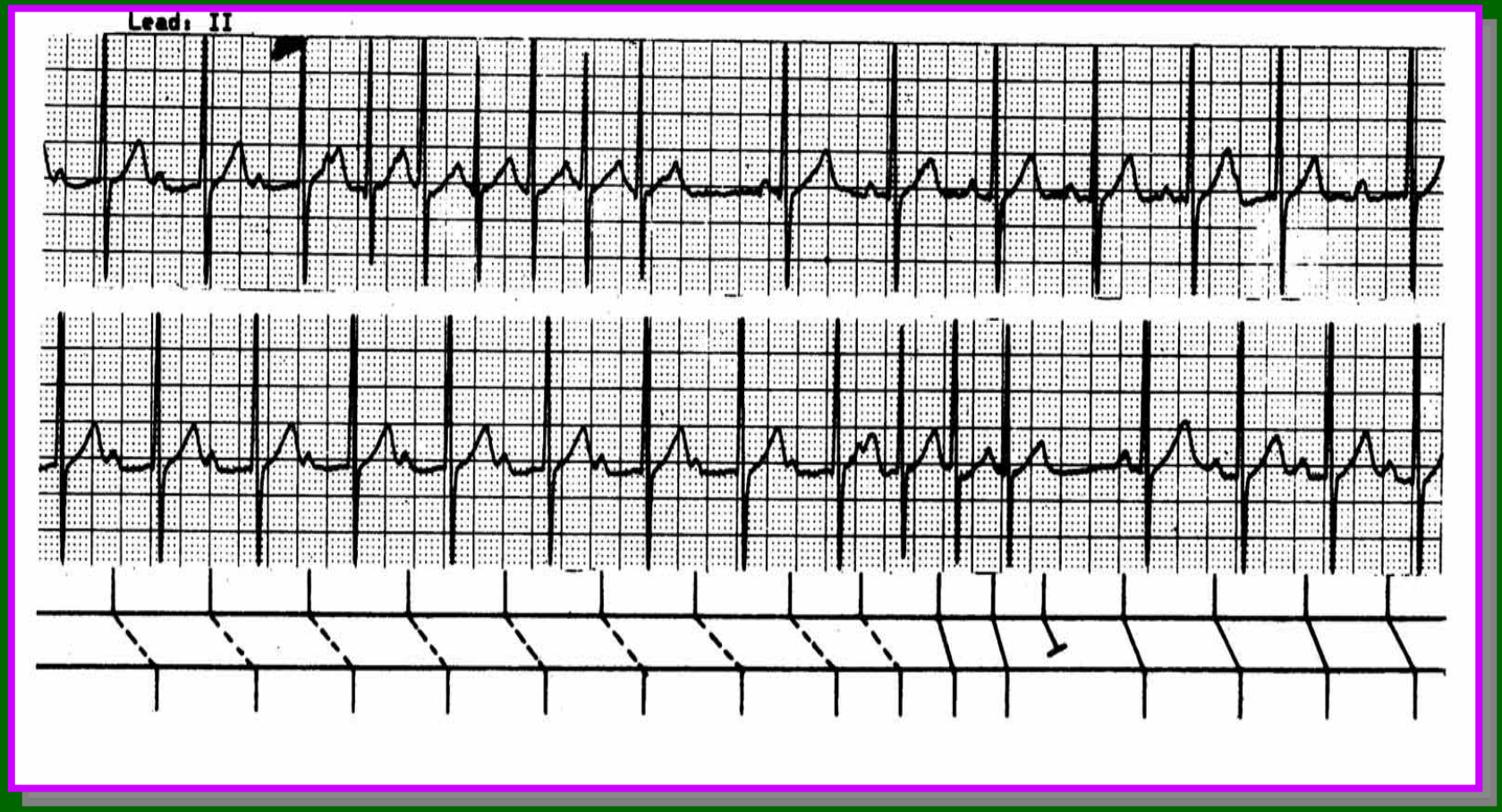

Fisch C, 2000

ECG Manifestations of Dual AV Nodal Conduction

Mamlin and Fisch, AJC 1965

Anatomic-Physiologic Relation

Anatomic Substrate of Dual AVN

- Fast AV nodal pathway
  - Anterior (Superior) atrionodal connections
- Slow AV nodal pathway
  - Posterior (Inferior) atrionodal connections
  - Posterior nodal extension

His Electrogram Alternans

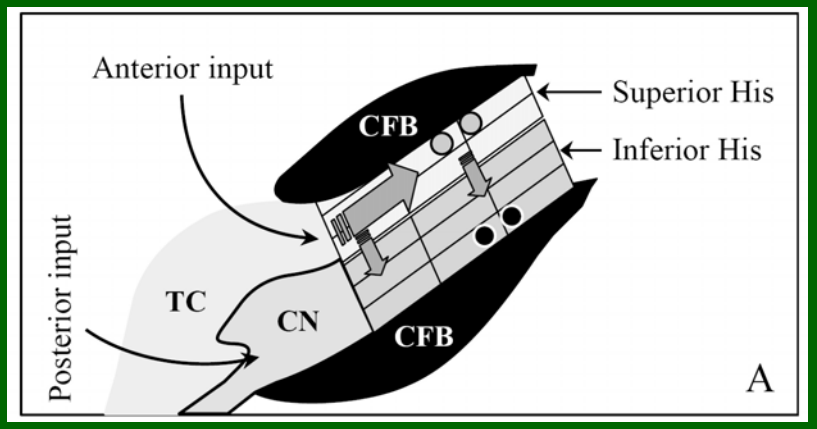

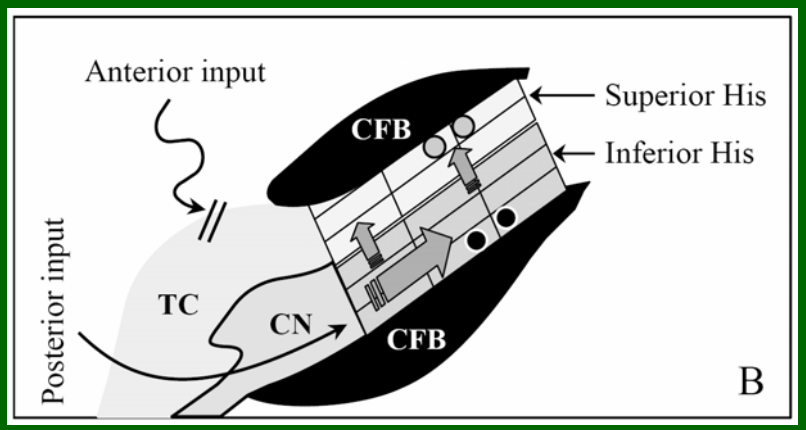

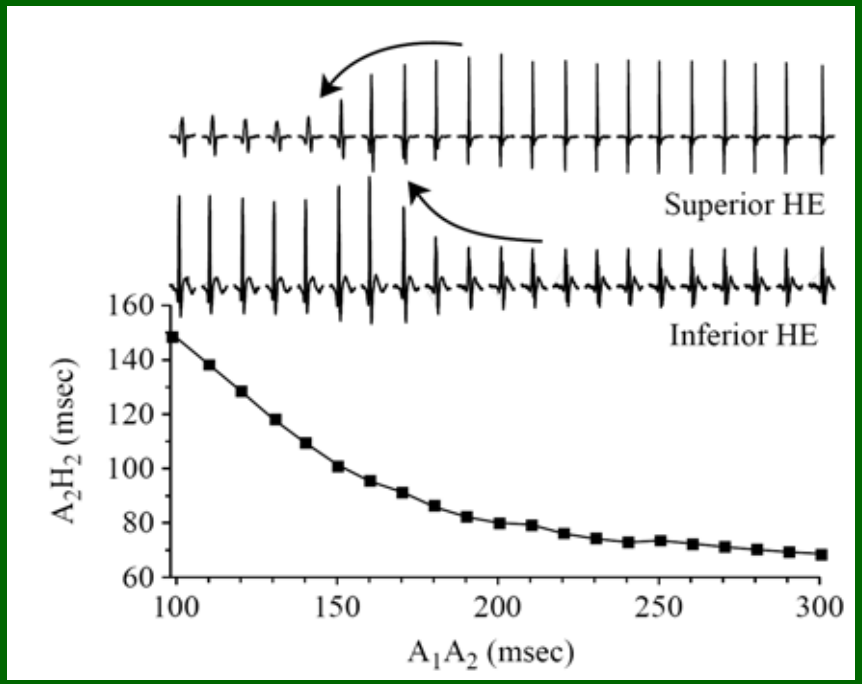

Zhang Y et al, Circulation 2001

Atrial Inputs and Dual AV Nodal Pathways

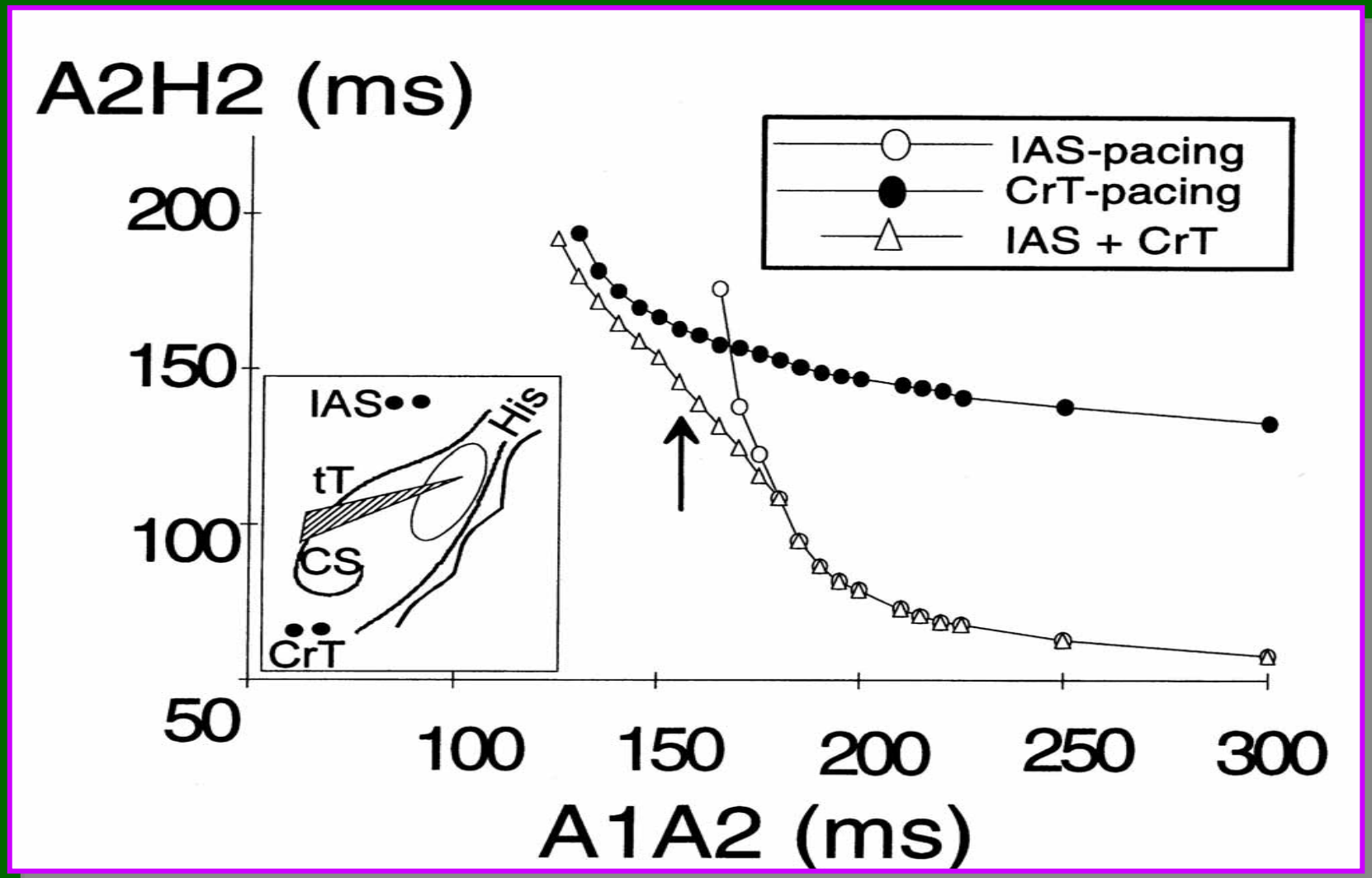

Tchou P, JCE 1997

PNE and Slow Pathway

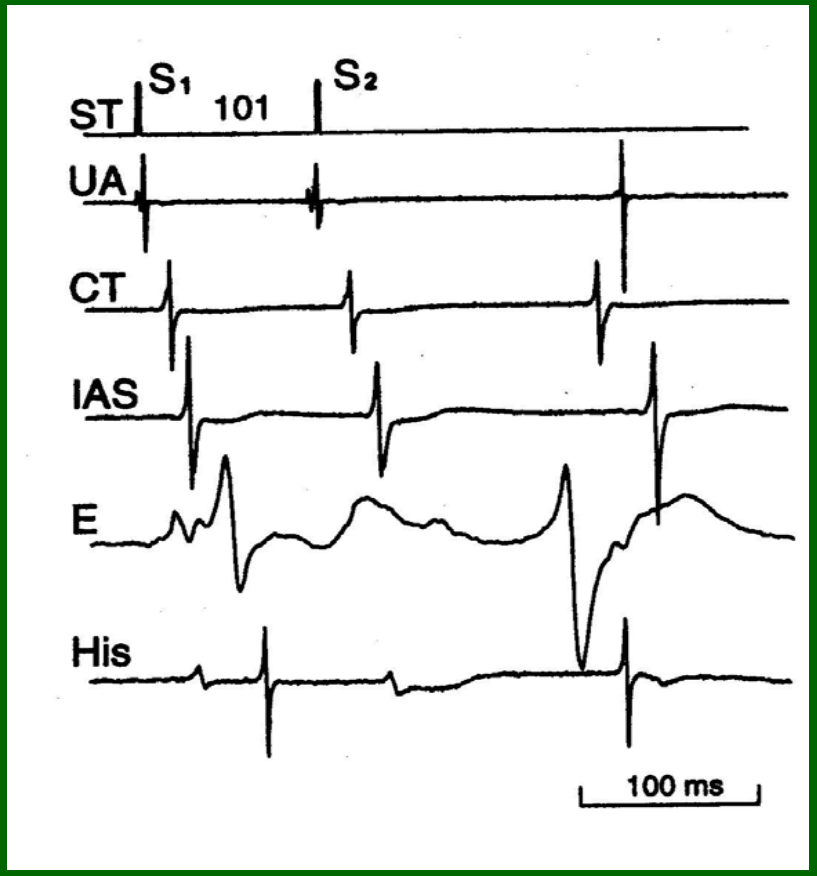

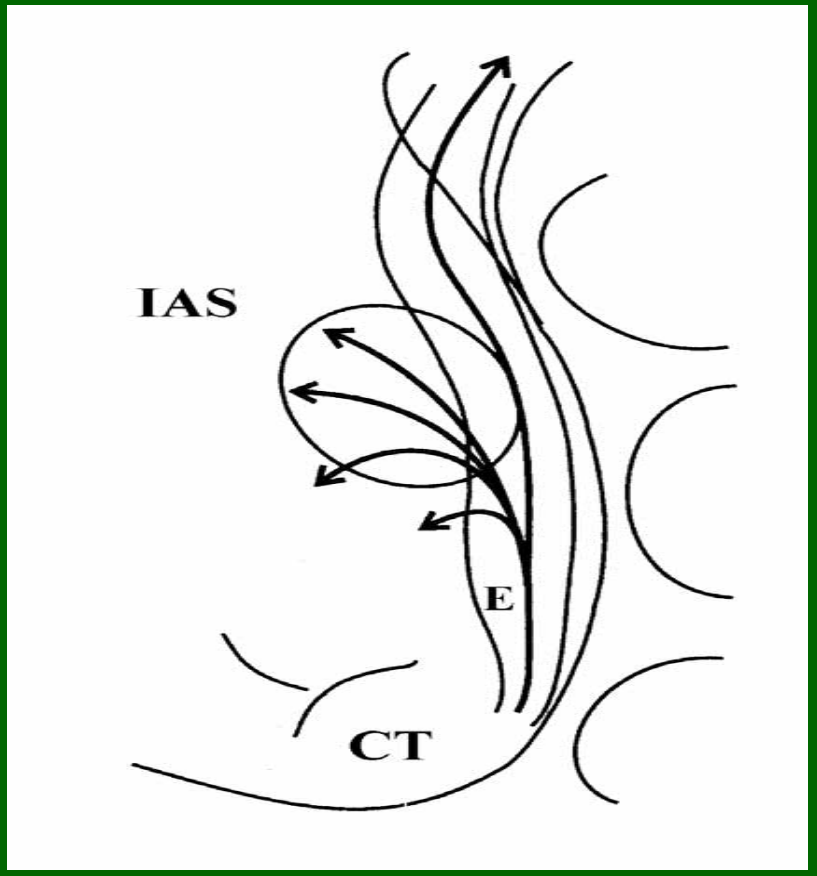

Medkour and Billette, Circulation 1998

Atrial Inputs and Dual AV Nodal Pathways

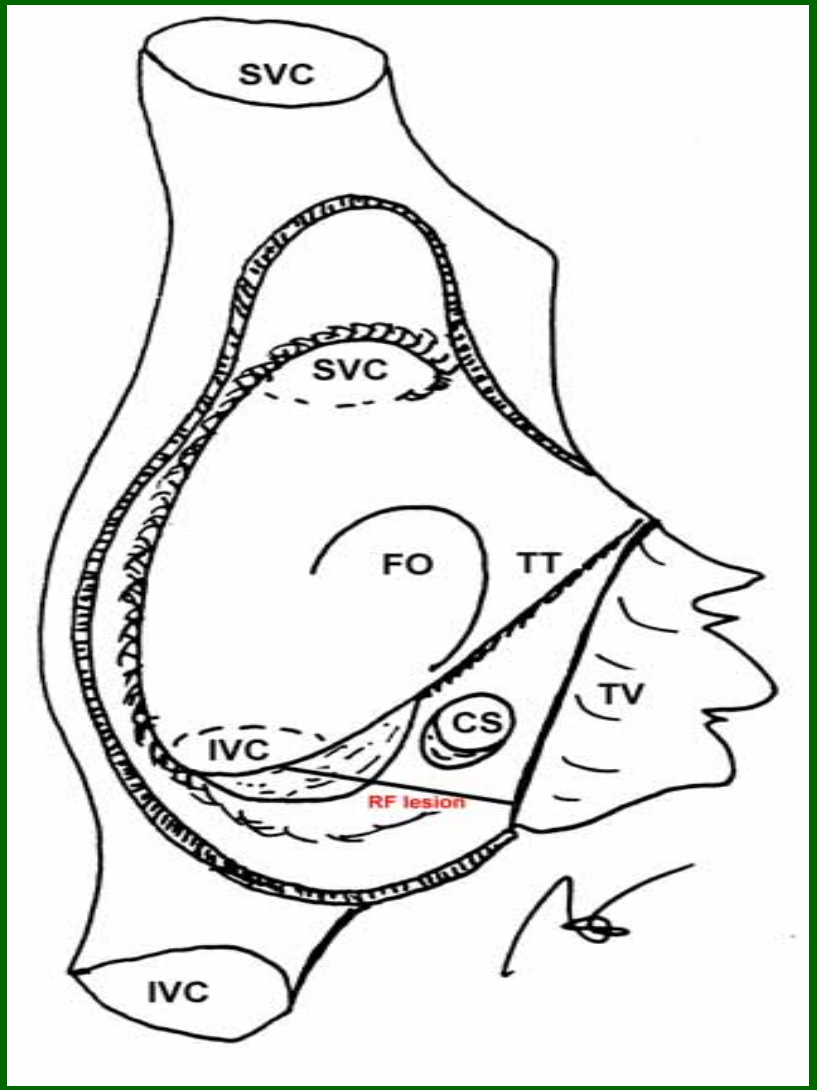

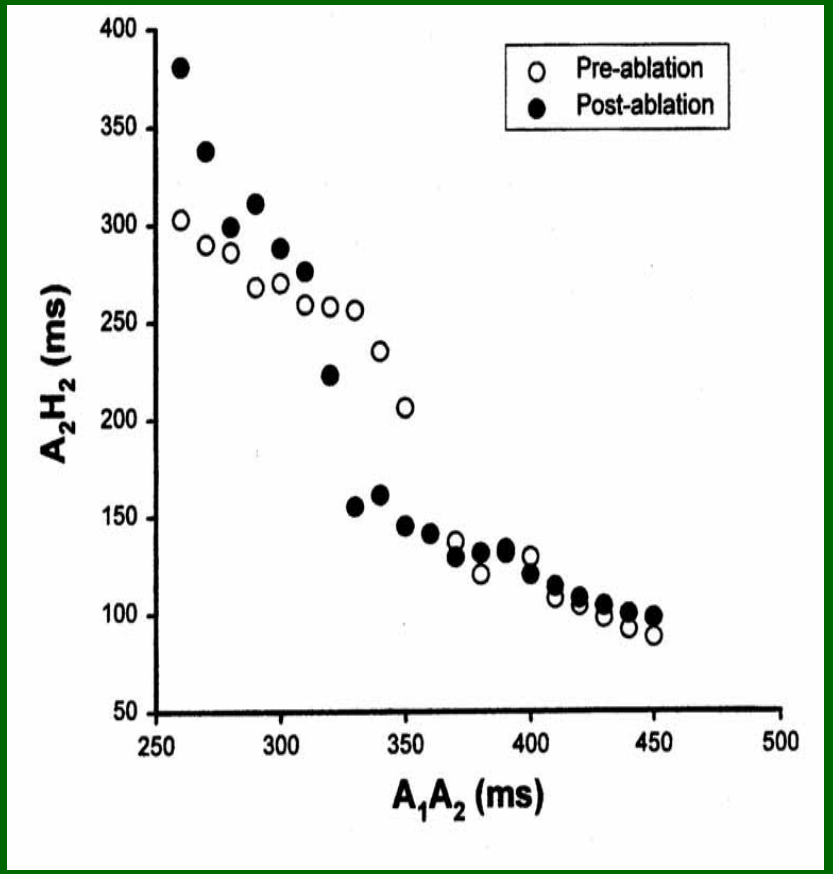

Tai CT. et al., Circulation 2001

Effects of Cavotricuspid Isthmus Ablation on Atrioventricular Node Electrophysiology in Patients With Typical Atrial Flutter

Ching-Tai Tai, MD; Chin-Feng Tsai, MD; Ming-Hsiung Hsieh, MD; Wei-Shiang Lin, MD; Yung-Kuo Lin, MD; Shih-Huang Lee, MD; Wen-Chung Yu, MD; Yu-An Ding, MD, PhD; Mau-Song Chang, MD; Shih-Ann Chen, MD

Background—The atrial musculature in the cavotricuspid isthmus is a part of posterior inputs to the AV node. In patients with typical atrial flutter, effects of radiofrequency ablation of this isthmus on AV node conduction are still unknown.

Methods and Results—This study included 16 patients with clinically documented typical atrial flutter. Group 1 had 8 patients without and group 2 had 8 patients with dual AV nodal pathway physiology. Electrical pacing from the interatrial septum and low right atrium was performed to evaluate antegrade AV node function before and after ablation of the cavotricuspid isthmus. In group 1, the AV node conduction properties were similar before and after ablation. In group 2, the AV node Wenckebach cycle length and maximal AH interval during low right atrium (356±58 versus 399±49 ms, P=0.008; 303±57 versus 376±50 ms, P=0.008) and interatrial septum (365±62 versus 393±59 ms, P=0.008; 324±52 versus 390±60 ms, P=0.008) pacing were significantly longer after ablation. Elimination of the slow pathway after ablation was noted in 2 patients, including 1 with AV nodal reentrant echo beats.

Conclusions—Radiofrequency ablation of the cavotricuspid isthmus was effective in eliminating typical atrial flutter without injury of antegrade fast AV node conduction. The atrial musculature in the cavotricuspid isthmus significantly contributed to the slow AV node conduction. (***Circulation*. 2001;104:1501-1505.**)

AV Nodal Reentrant Tachycardia

- Typical type
  - Slow-Fast (α-β)
- Atypical type
  - Fast-Slow (β- α)
  - Fast-Intermediate (β-γ)
  - Slow-Intermediate (α- γ)

Wu et al, AHJ 1994;127:83

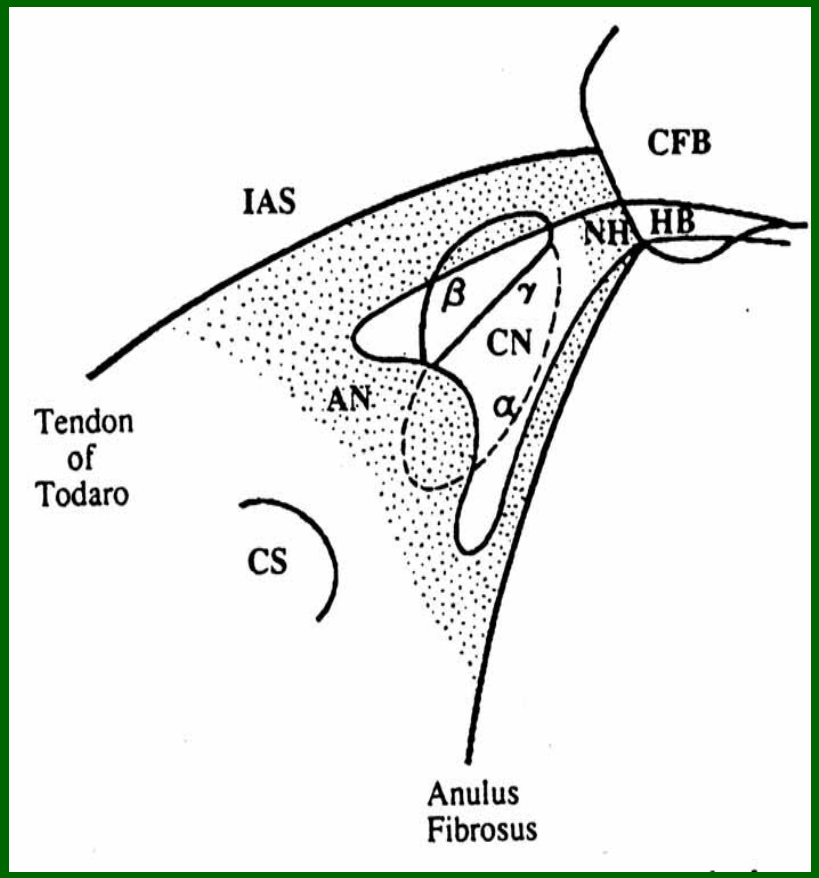

Slow-Fast AVNRT

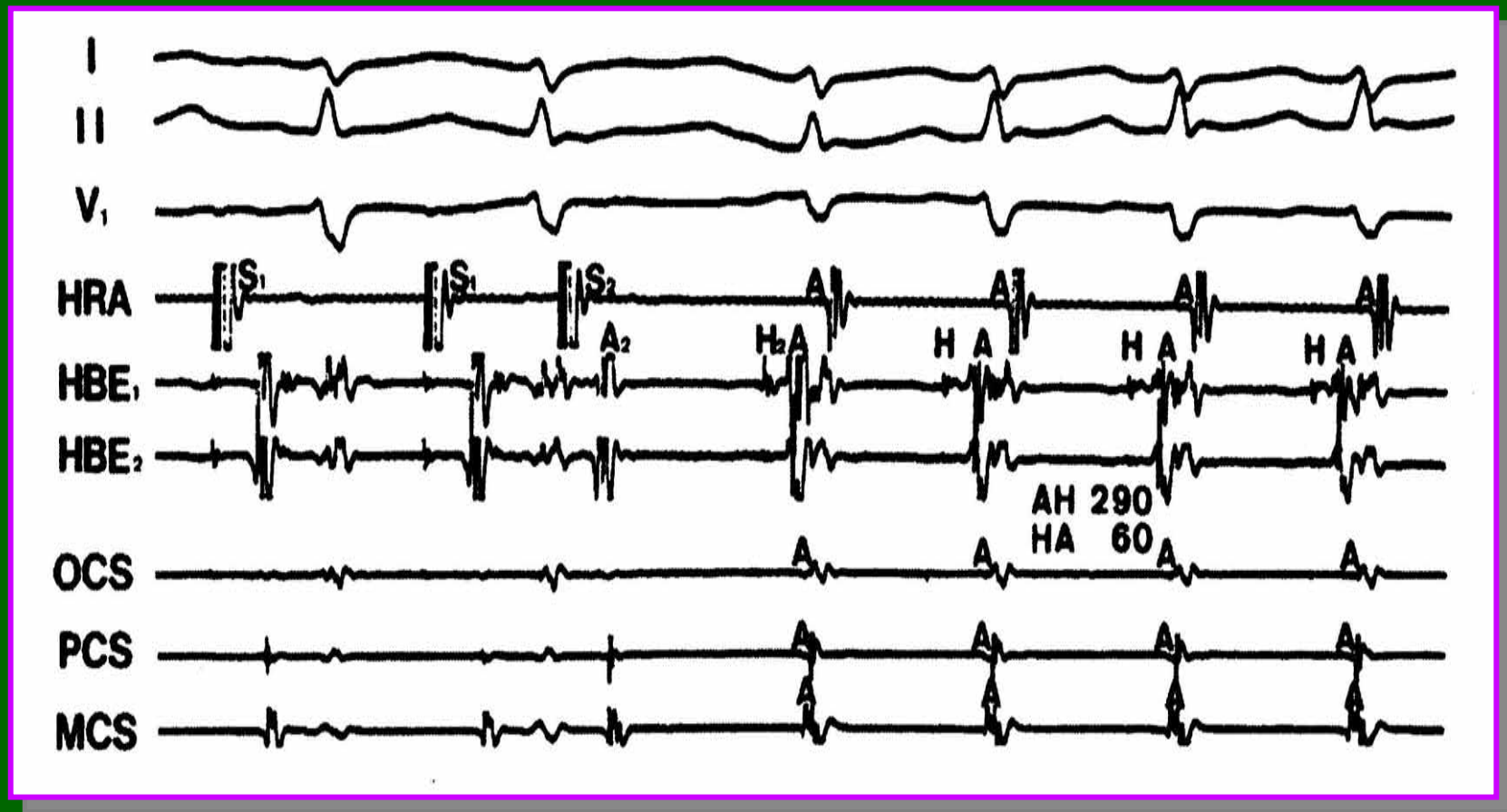

Slow-Fast AVNRT

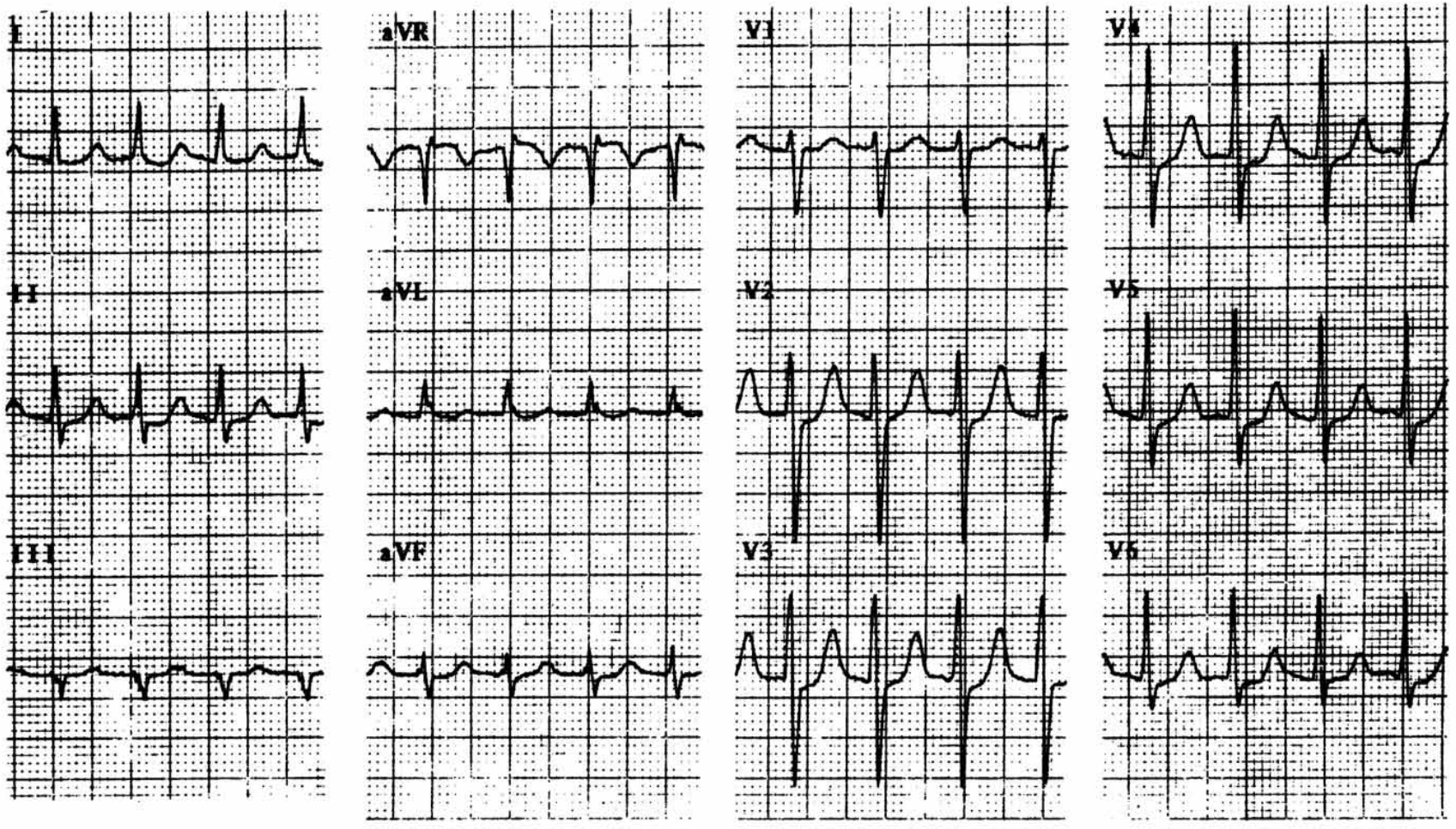

Slow-Fast AVNRT

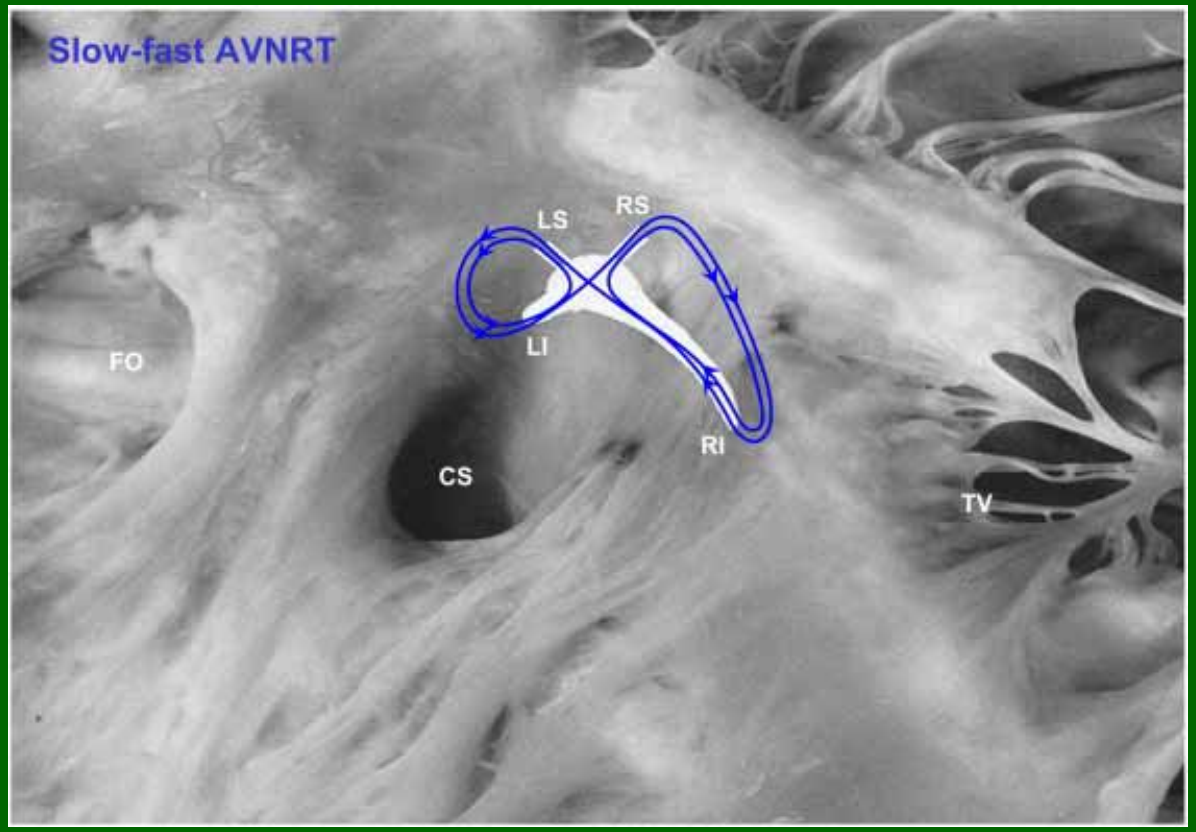

Katritsis et al, Heart Rhythm 2007

Fast-Slow AVNRT

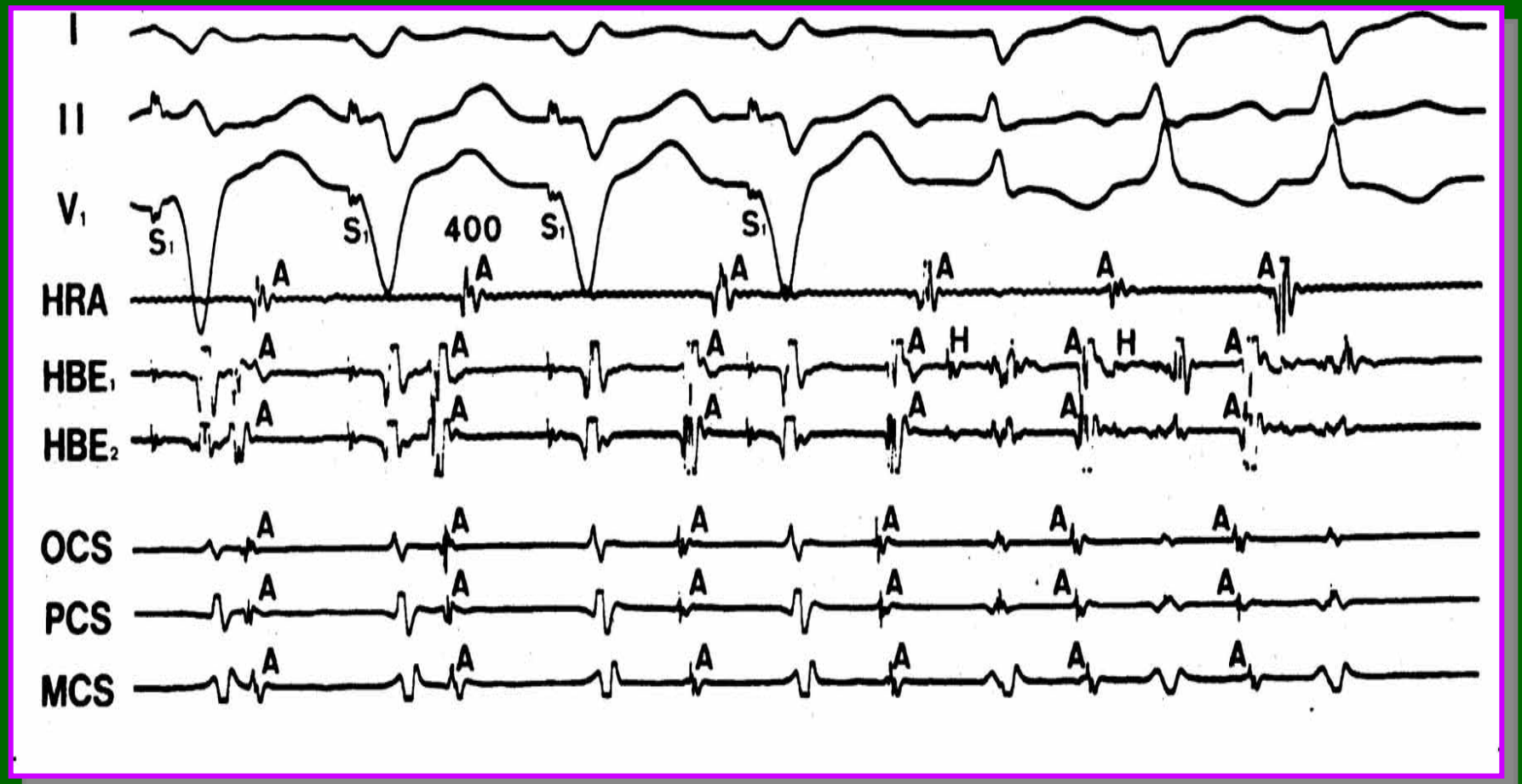

Fast-Slow AVNRT

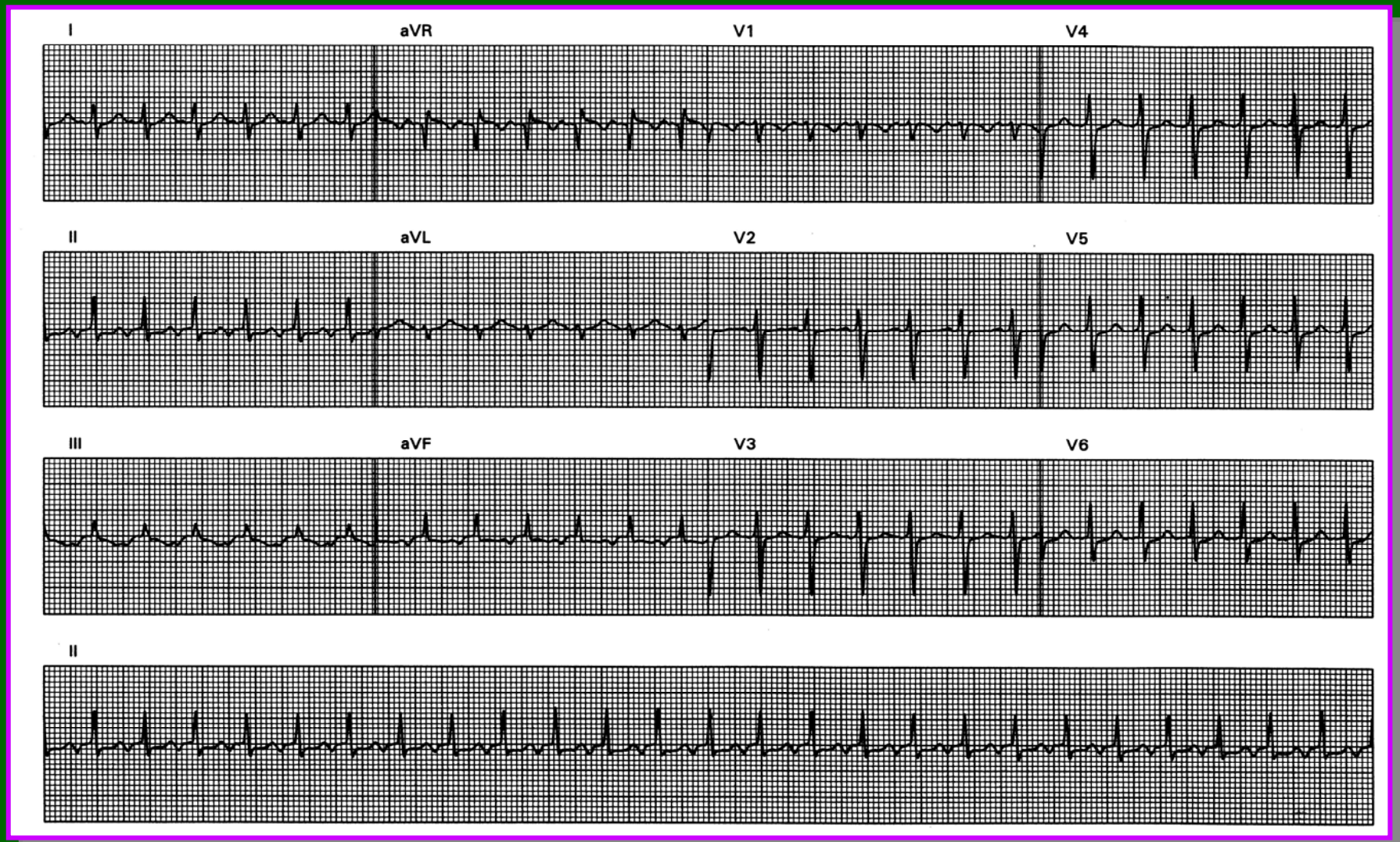

Fast-Slow AVNRT

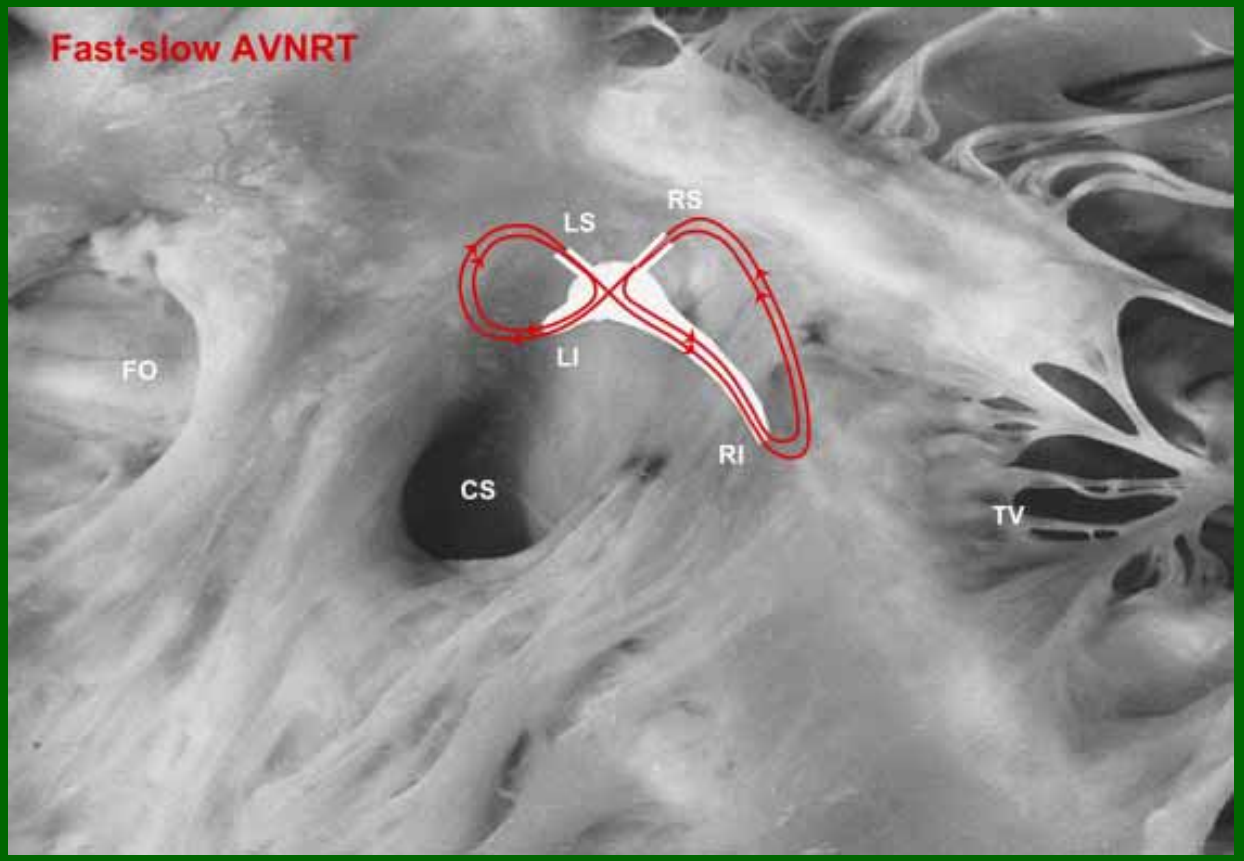

Katritsis et al, Heart Rhythm 2007

Slow-Slow AVNRT

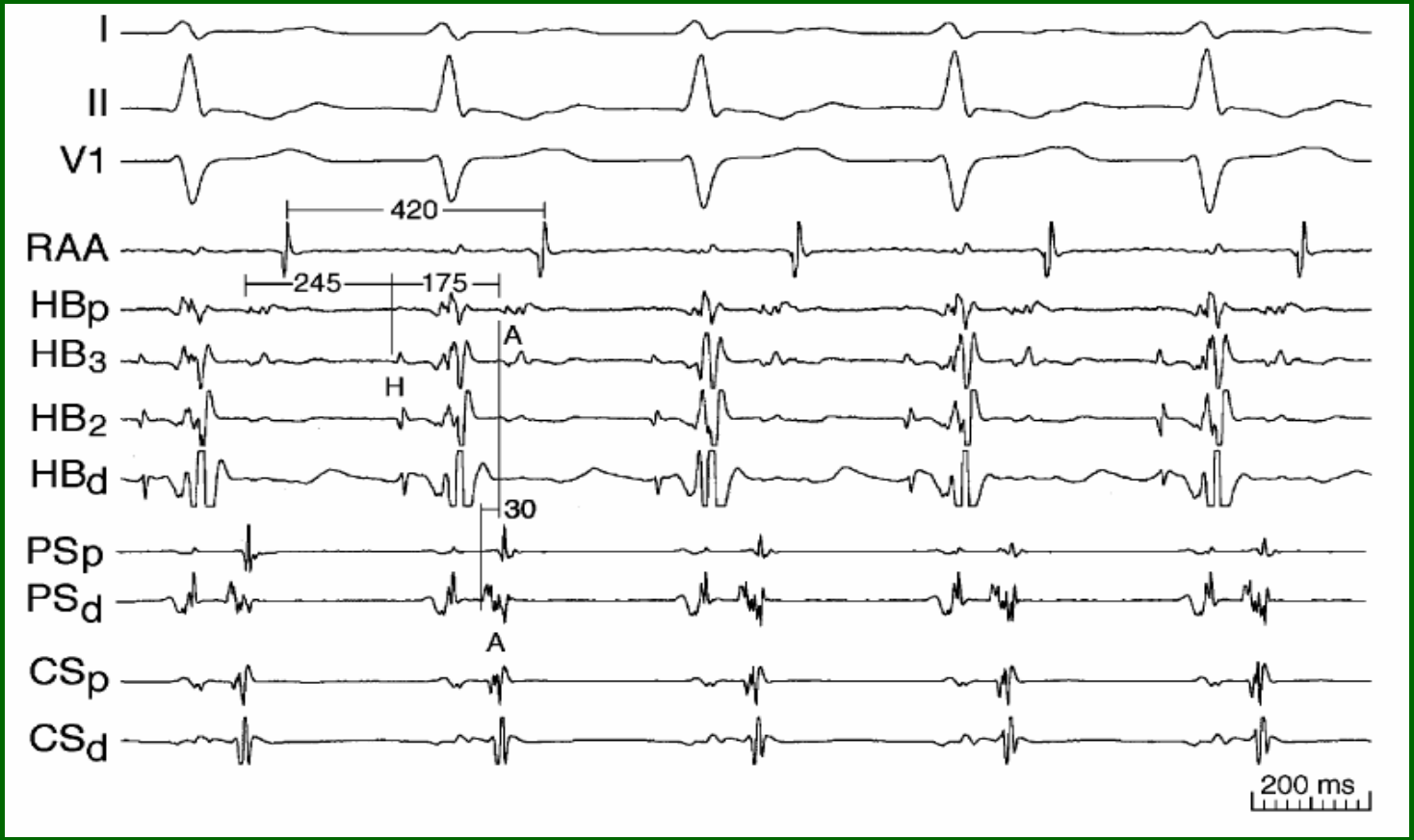

Slow-Slow AVNRT

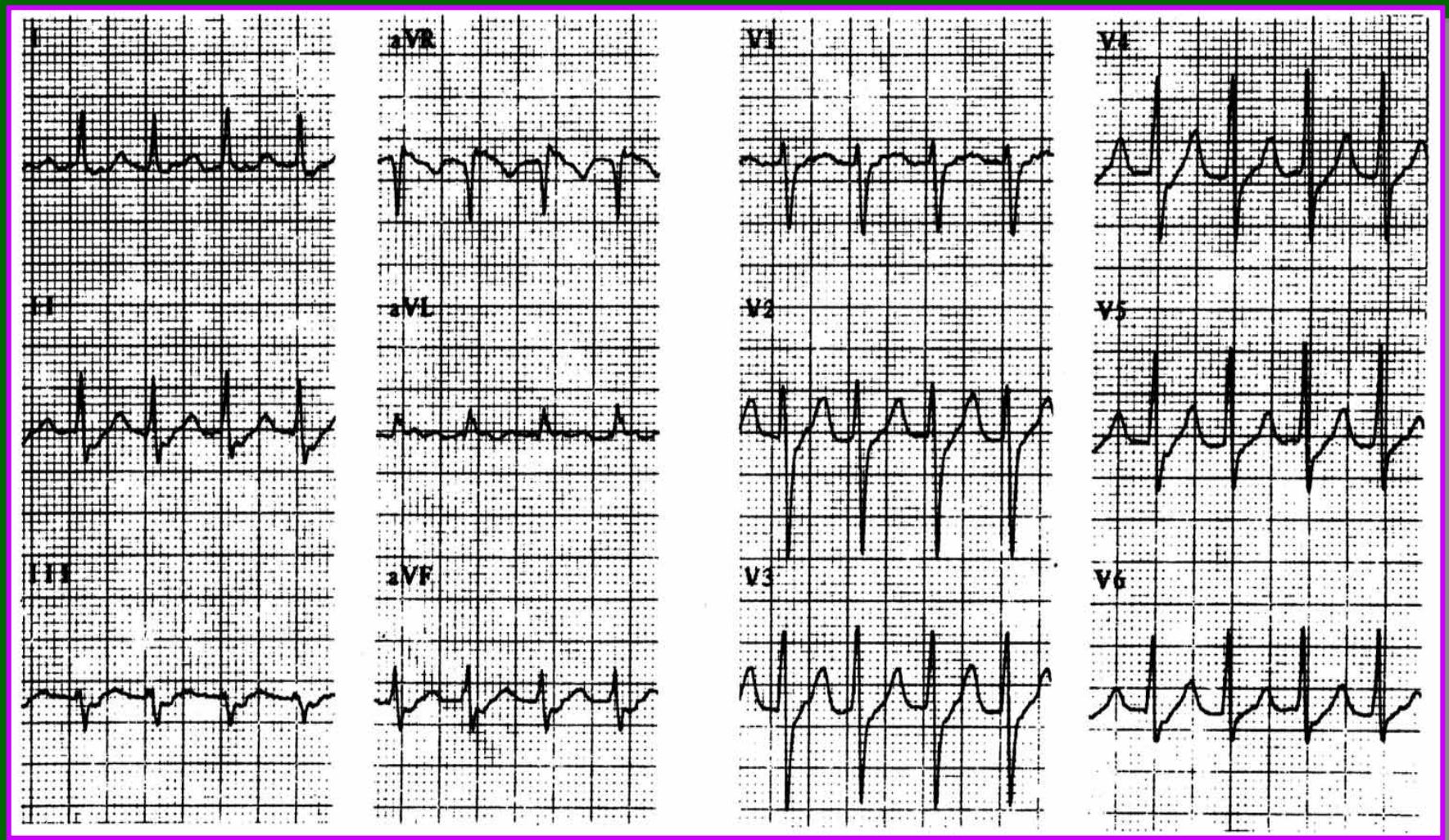

Slow-Slow AVNRT

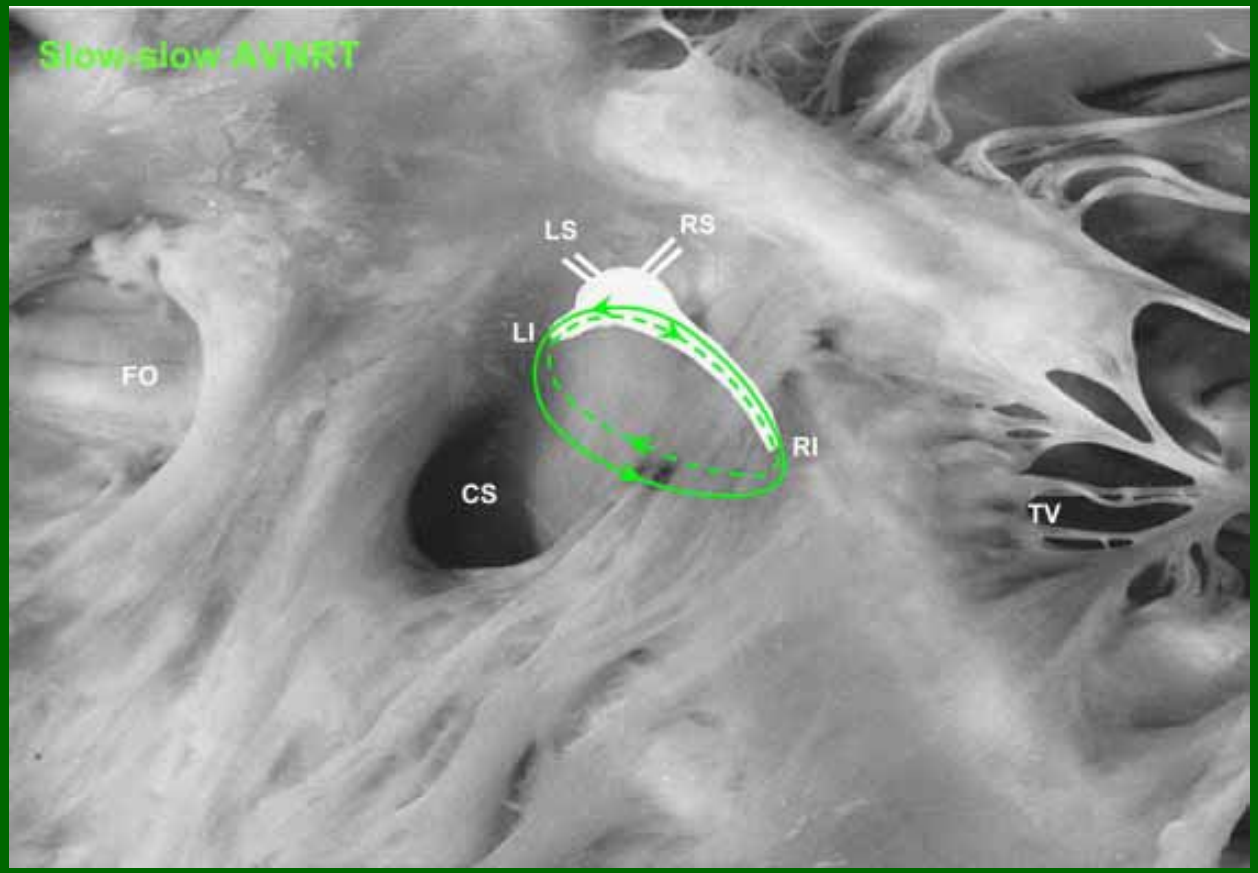

Katritsis et al, Heart Rhythm 2007

Various Types of AVNRT

TABLE II Characteristics in Different Types of Atrioventricular Nodal Reentry Tachycardia in Group I Patients (n = 36)

	Types of Tachycardia				
	I	II	III	IV	V
Number of patients	22 (61%)	8 (22%)	30 (83%)	16 (44%)	1 (3%)
Anterograde conduction	Fast	Fast	Slow	Slow	Slow
Retrograde conduction	Slow	Intermediate	Fast	Intermediate	Slow
TCL (ms)	348 ± 60	268 ± 33	373 ± 61	416 ± 74	590
AH interval (ms)	70 ± 15	96 ± 22	312 ± 61	272 ± 82	320
HA interval (ms)	278 ± 59	186 ± 29	57 ± 15	145 ± 34	270

Data are expressed as mean ± SD unless otherwise noted.
TCL = tachycardia cycle length.

Tai CT, Am J Cardiol, 1996

Diagnosis of JET

- Clinical presentation of congenital JET usually ranges from birth to 4 weeks of age
- High percentage of patients had congestive heart failure
- Narrow QRS complex tachycardia (160 to 300 bpm) with AV dissociation

JET

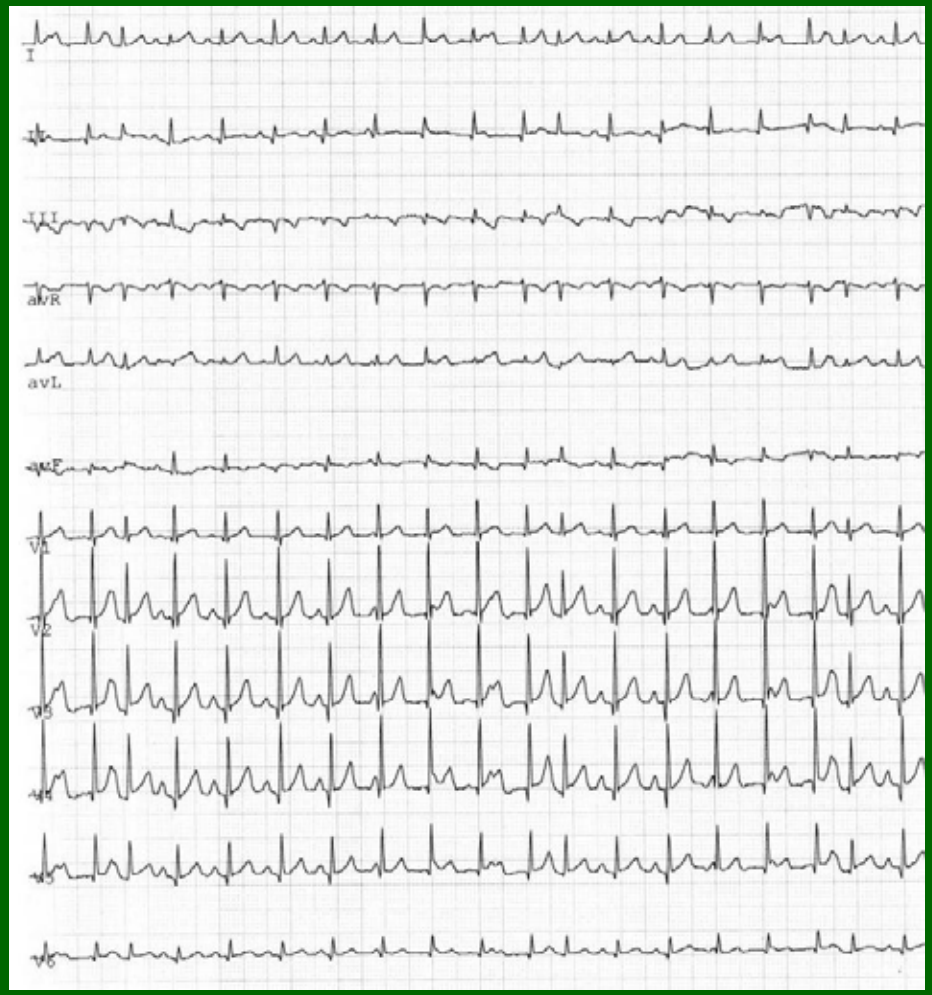

Electrophysiological Mechanism

- Abnormal automaticity originates from the atrial inputs to the junction, distal compact node or the His bundle.
- Warming-up at its onset and cooling down at its termination
- It is not inducible or terminated by programmed stimulation

Differential Diagnosis

- When a PAC is timed to His refractoriness, any perturbation of the subsequent His indicates anterograde slow pathway conduction and confirms a diagnosis of AVNRT.
- A PAC that Advances the His potential immediately after it without terminating tachycardia indicates that retrograde fast pathway is not essential for the circuit and confirms a diagnosis of JET.
- H-Ap–H-At $< 0 \rightarrow$ AVNRT, H-Ap–H-At $\geq 0 \rightarrow$ JET

AVNRT

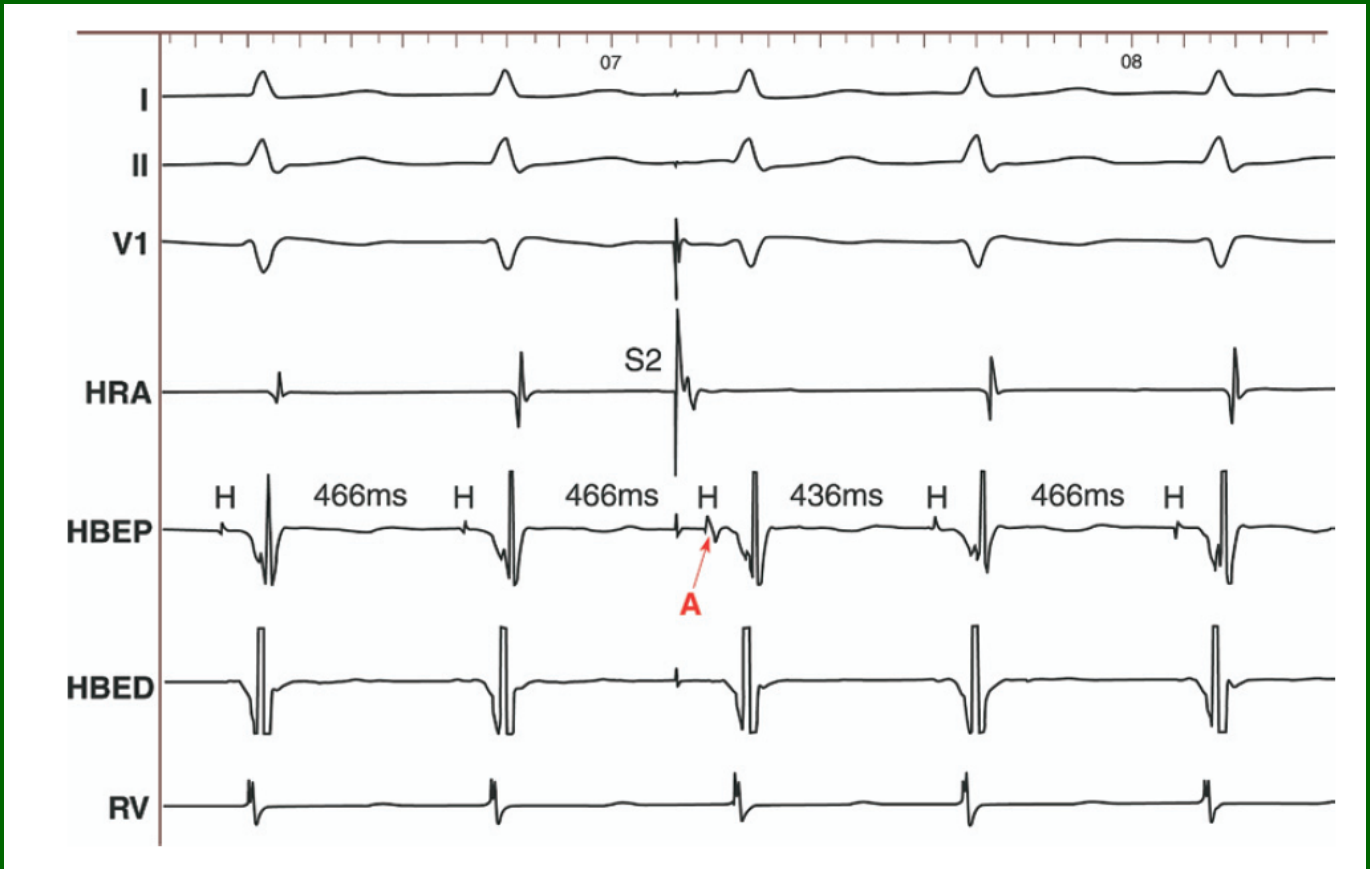

Padanilam et al, JACC 2008

JET

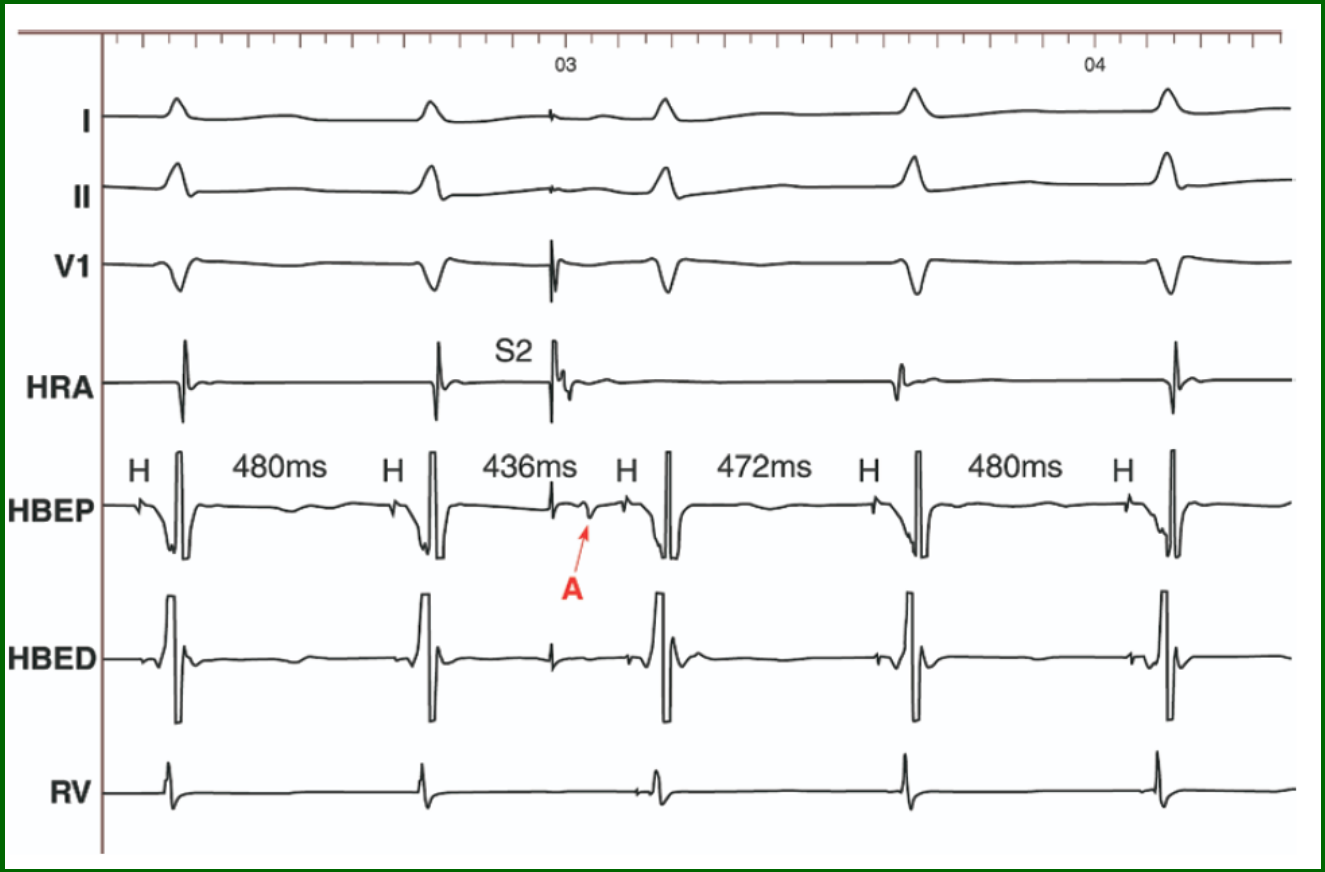

Padanilam et al, JACC 2008

RF Catheter Ablation of AVNRT

- Anterior anatomic approach
- Posterior anatomic approach
- High-frequency slow pathway potential guided approach
- Low-frequency slow pathway potential guided approach

Anatomic Approach

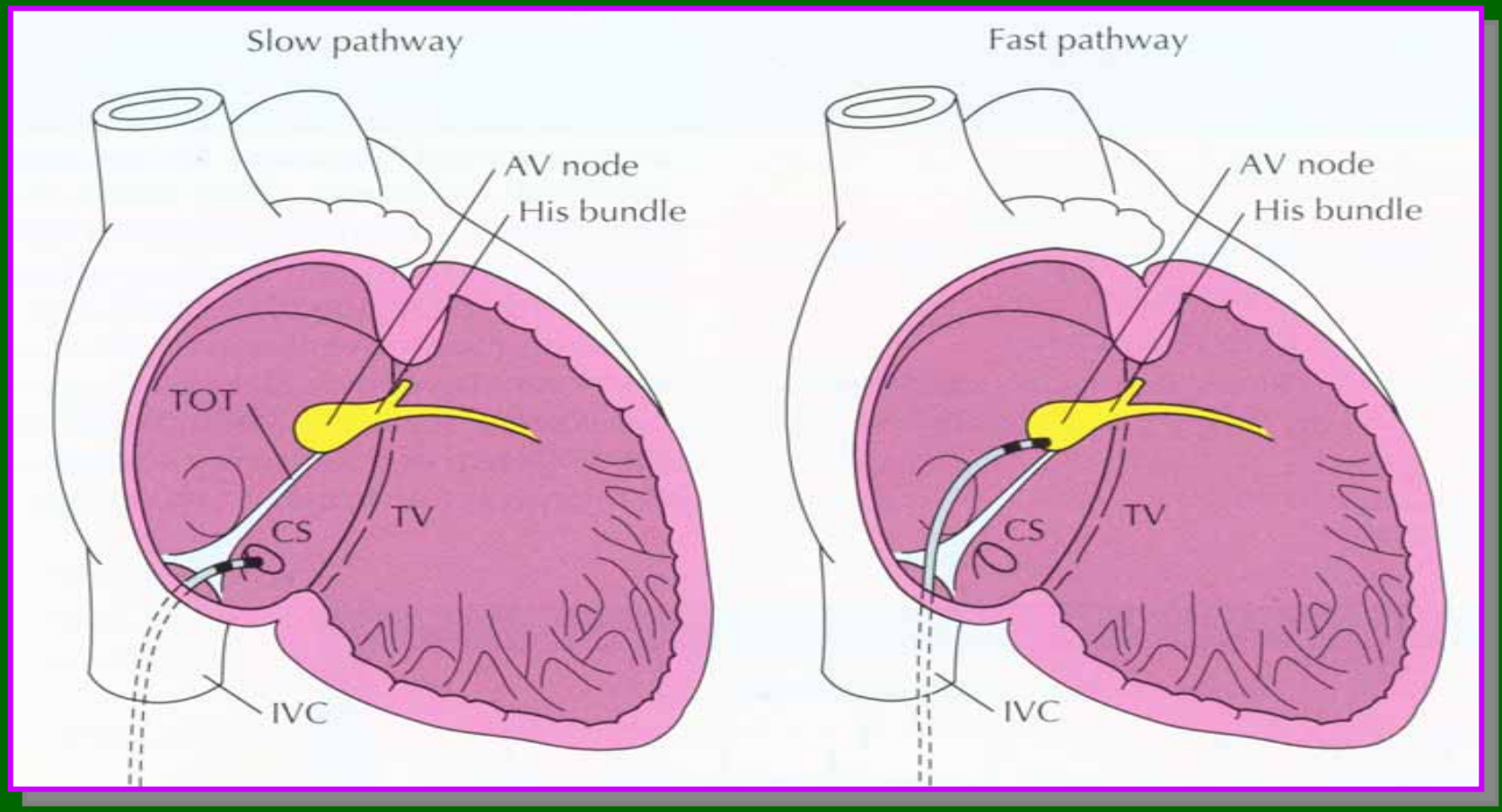

Electrophysiological Approach

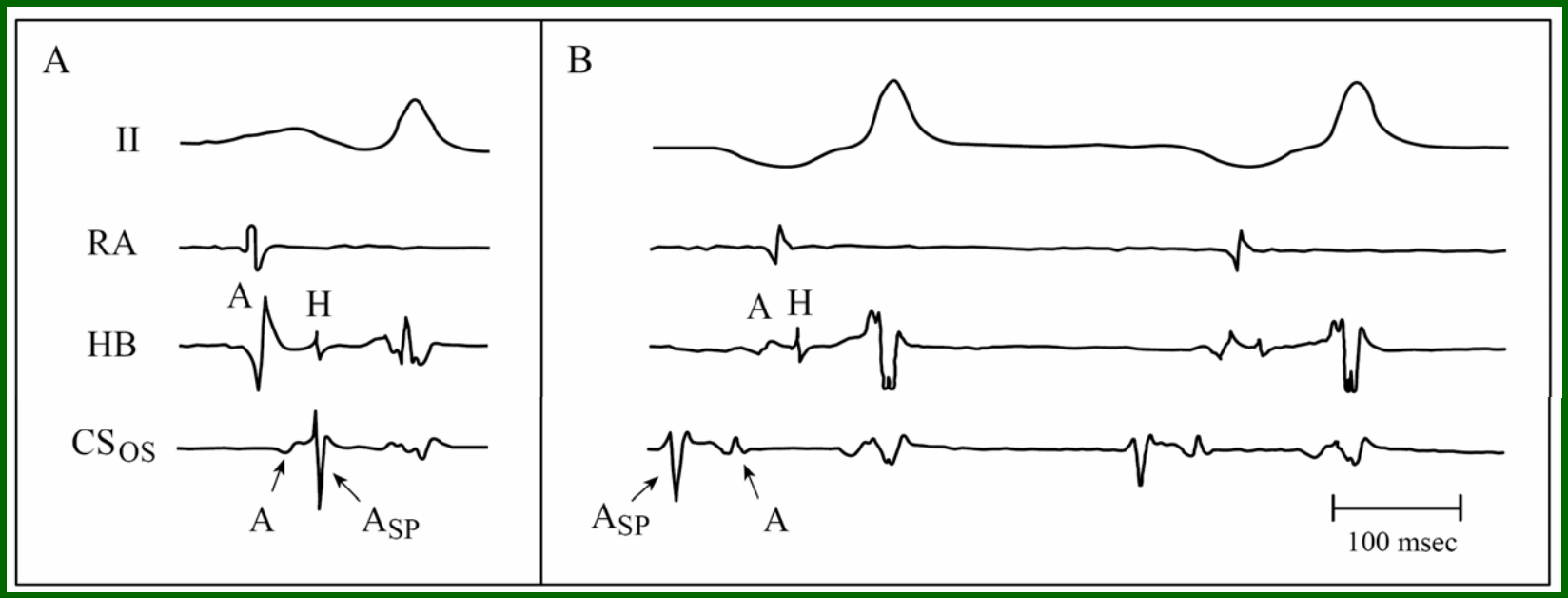

Jackman et al, N Engl J Med 1992

RF Ablation of Slow Pathway

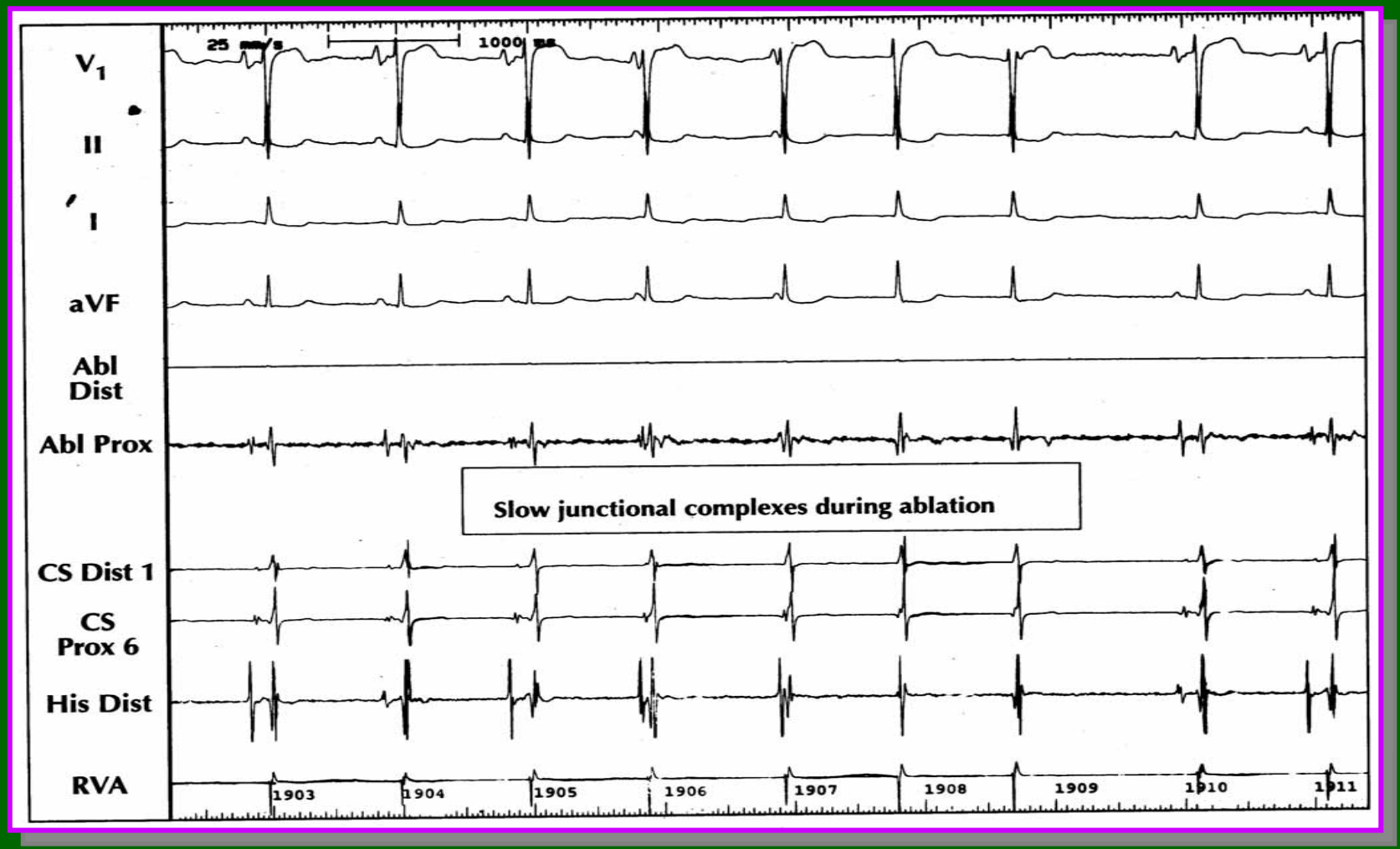

Results of AV Junctional Modification

	No. of Patients	Success (%)	Recurrence (%)	Heart Block (%)
Jackman et al	80	79 (99)	0 (0)	1 (1)
Kay et al	242	239 (98)	16 (7)	3 (1)
Akhtar et al	193	188 (97)	—	2 (2)
Haissaguerre et al	64	64 (100)	0 (0)	0 (0)
Wu et al	100	97 (97)	1 (1)	3 (3)
Taipei VGH	760	752 (99)	14 (2)	5 (1)

Future Studies

- Uncover the cellular electrophysiological mechanisms responsible for fast and slow AV node conduction
- Define the exact tissue components of the reentrant circuit of AVNRT
- Study the long-term effects of RF ablation on AV conduction

Thank You for Your Attention