Fundamentals of EGM Interpretation and Rhythm Analysis

Christine Chiu-Man, MSc
Electrophysiology Pacemaker Technologist
The Hospital for Sick Children, Toronto, Canada

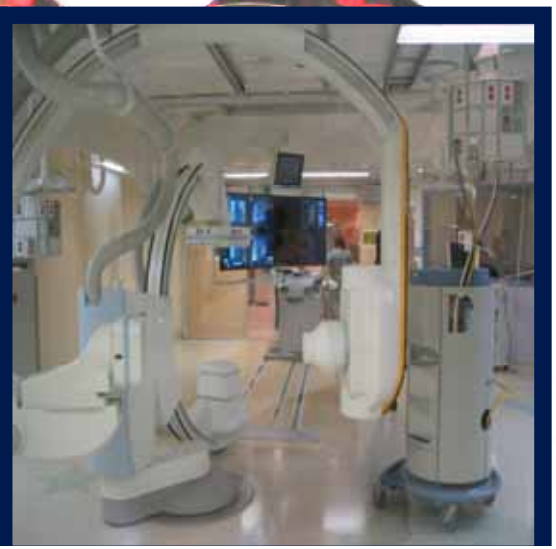

Intracardiac Electrogram 心内电图

- **Electrodes record the local electrical activity:**
  - **Sequence activation and timing**
- **Normal tissue will show high frequency and amplitude signals (eg. 10 to 250 Hz)**
- **Diseased tissue may show low amplitude fractionated signals**



Catheters

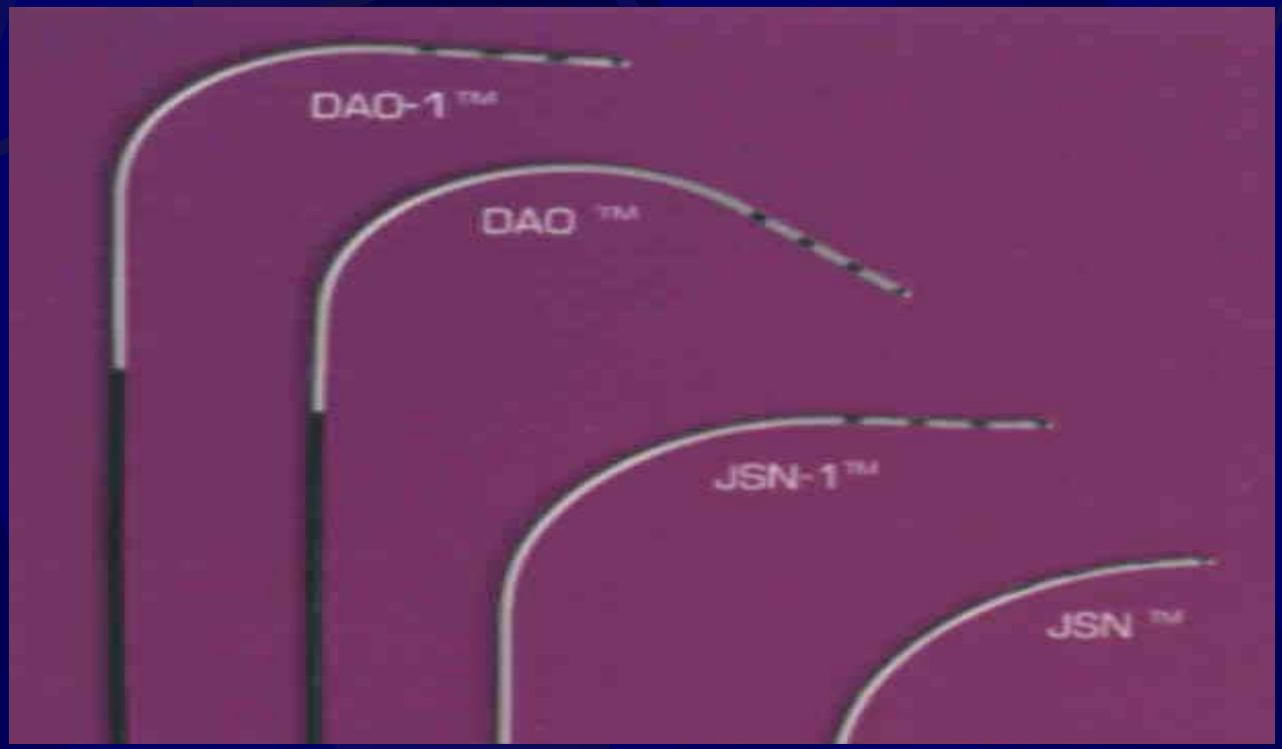

- Catheter curve
- Electrode spacing: 2mm, 5mm, 10mm, 2-10-2mm

How Are Electrograms Generated?

Band Pass Filter (Bipolar recordings)

- **High pass filter – removes low frequency (Respiratory or motion oscillations) Eg. 30 Hz**

- **Low pass filter – removes high frequency (Excessive large high frequency signals) Eg. 500Hz**

- **Band pass – 30 to 500 Hz allows signals between 30 and 500 Hz to pass through**

Stevenson JCE 2005;16:1017-1022.

Intracardiac Electrogram 心内电图

Morphology

Duration



Amplitude

Timing

Klitzner PACE 1990; 13:69-77

Intracardiac Electrogram 心内电图

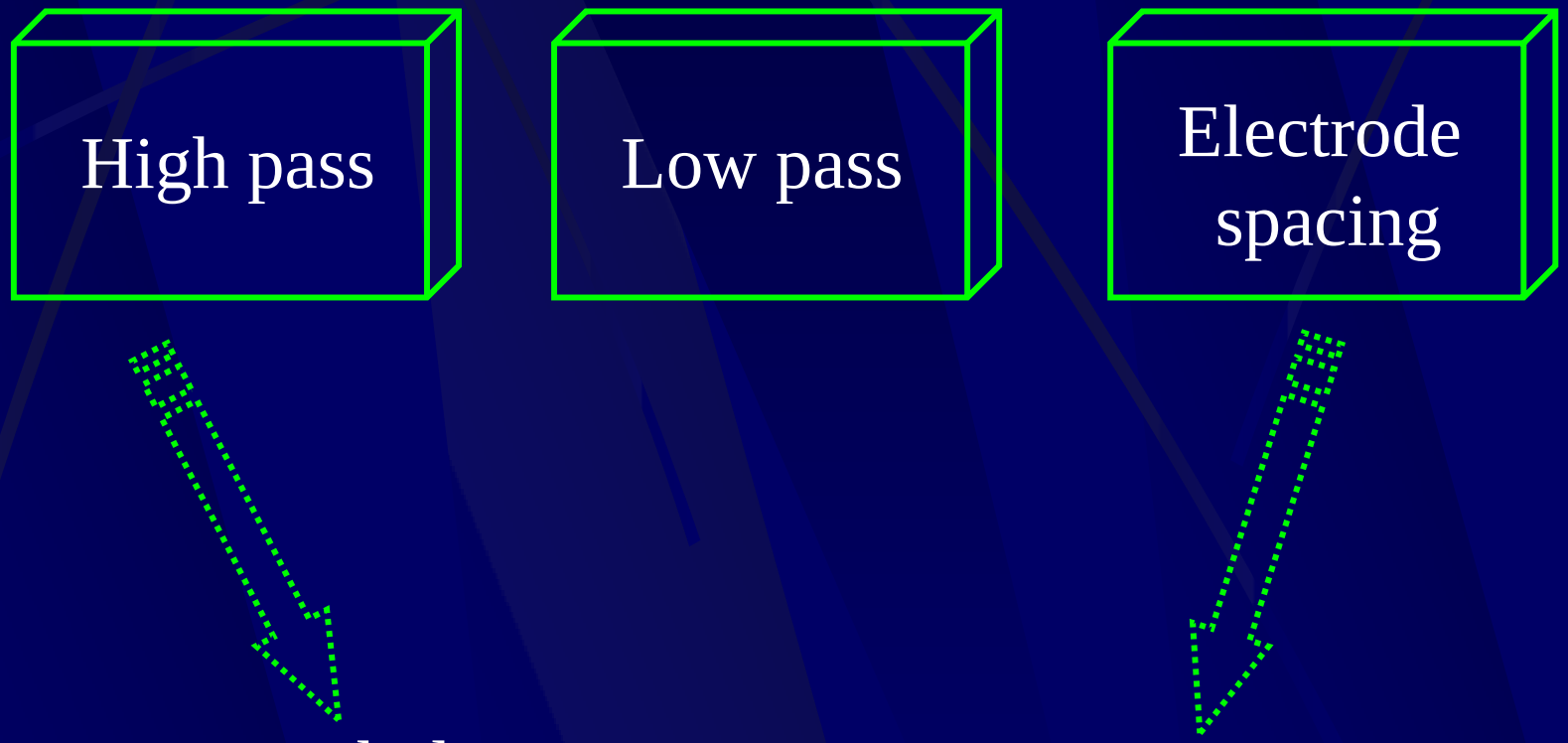

Klitzner PACE 1990; 13:69-77

Intracardiac Electrogram 心内电图

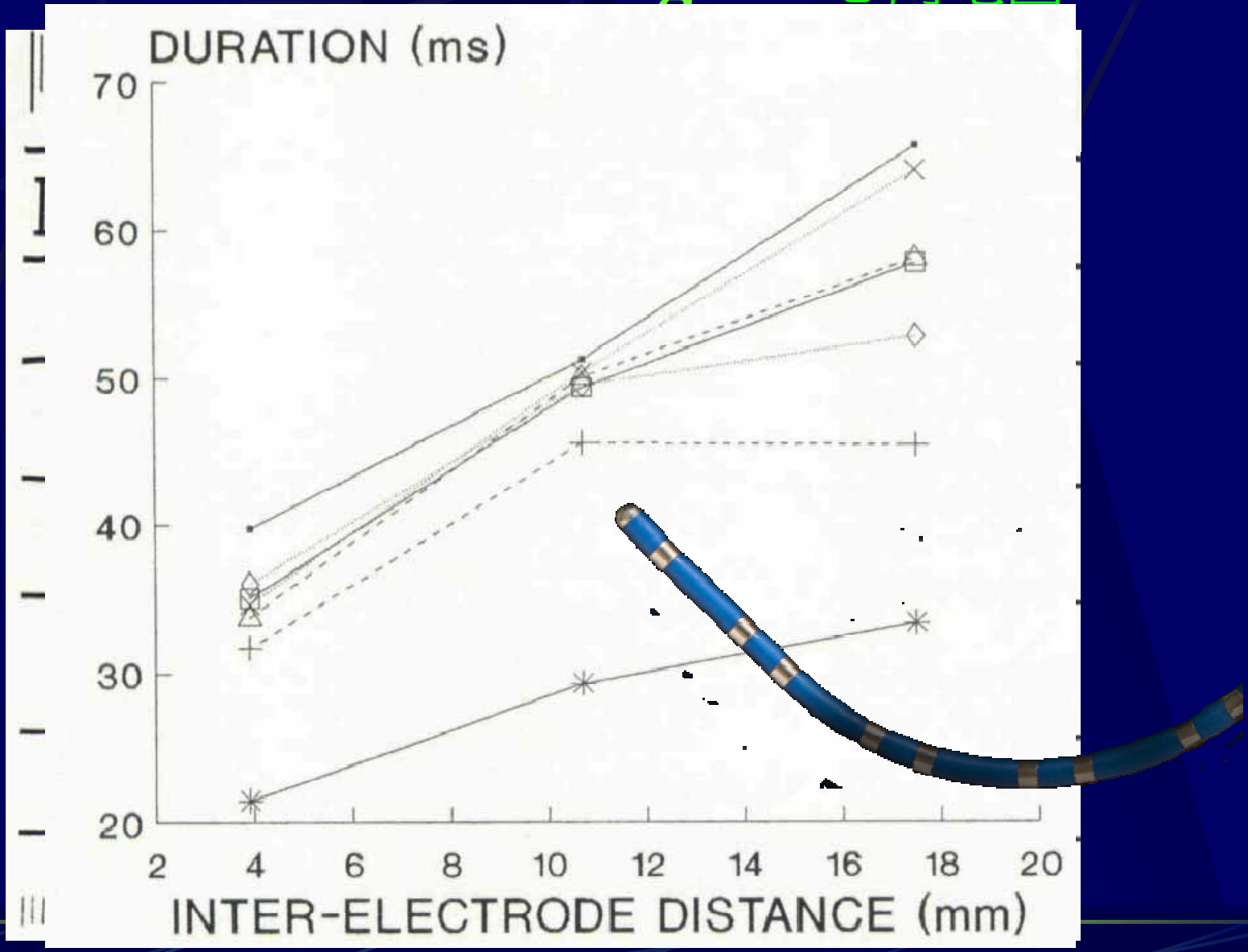

Klitzner PACE 1990; 13:69-77

Intracardiac Electrogram 심장내 전기도

- **Wavefront moving towards positive electrode (unipolar) -> positive deflection**

- **Wavefront moving away positive electrode (unipolar) -> negative deflection**

- **Bipolar: Electrical potential difference between two exploring electrodes at a given point in time.**

Stevenson JCE 2005;16:1017-1022.

Intracardiac Electrogram 심장내 전기도

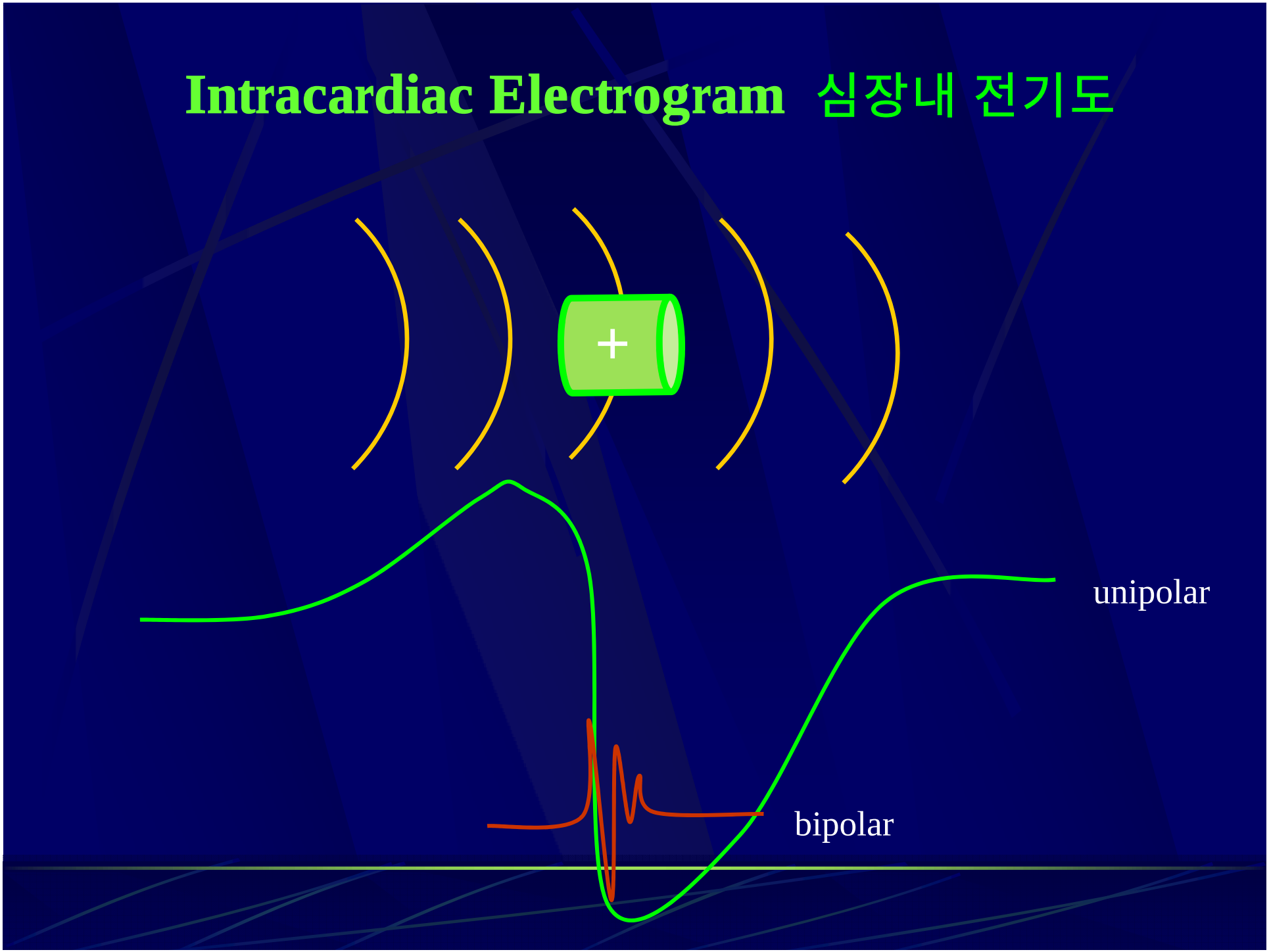

Mapping Considerations

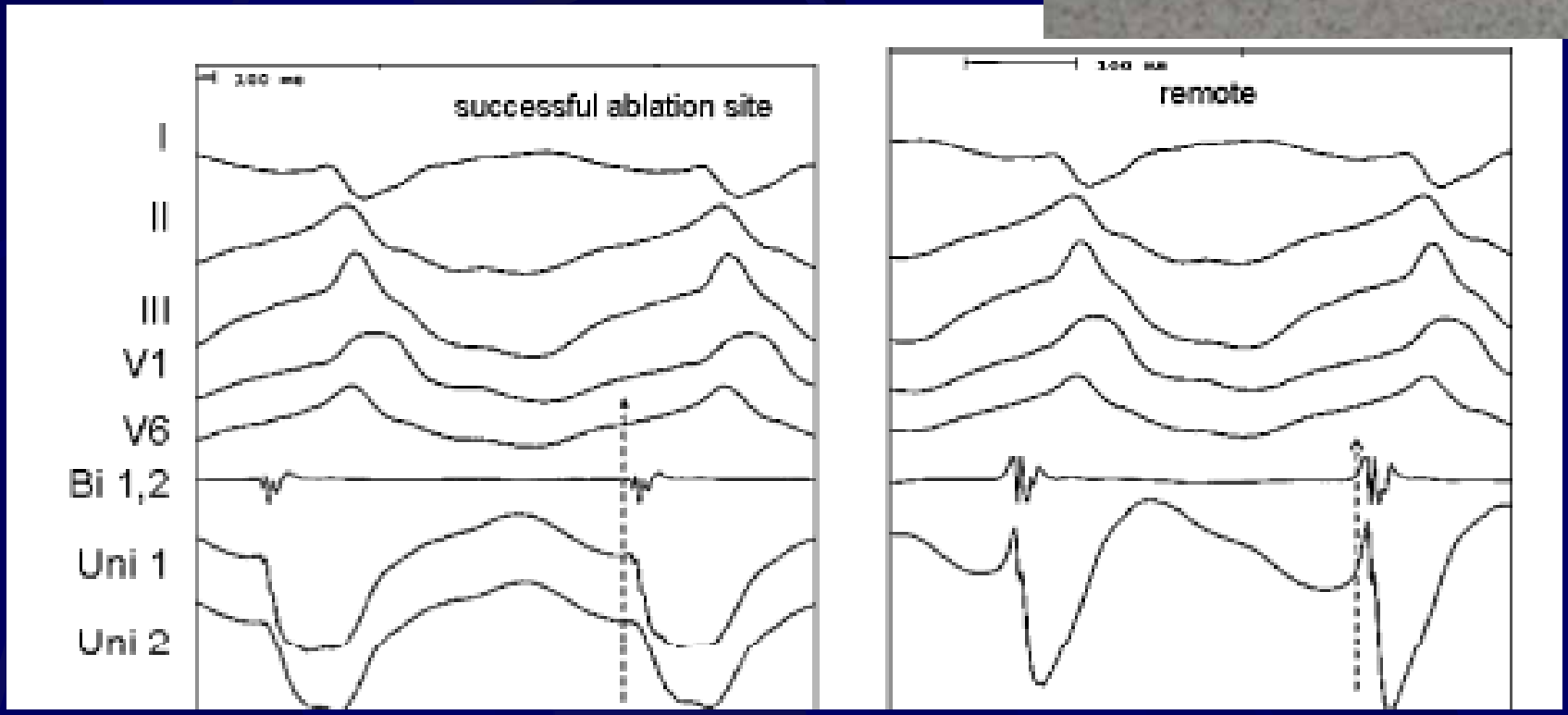

	Directionality
Unipolar: Max negative slope (QS)	Yes
Bipolar: Initial peak	No

Stevenson JCE 2005;16:1017-1022.

Intracardiac Electrogram 심장내 전기도

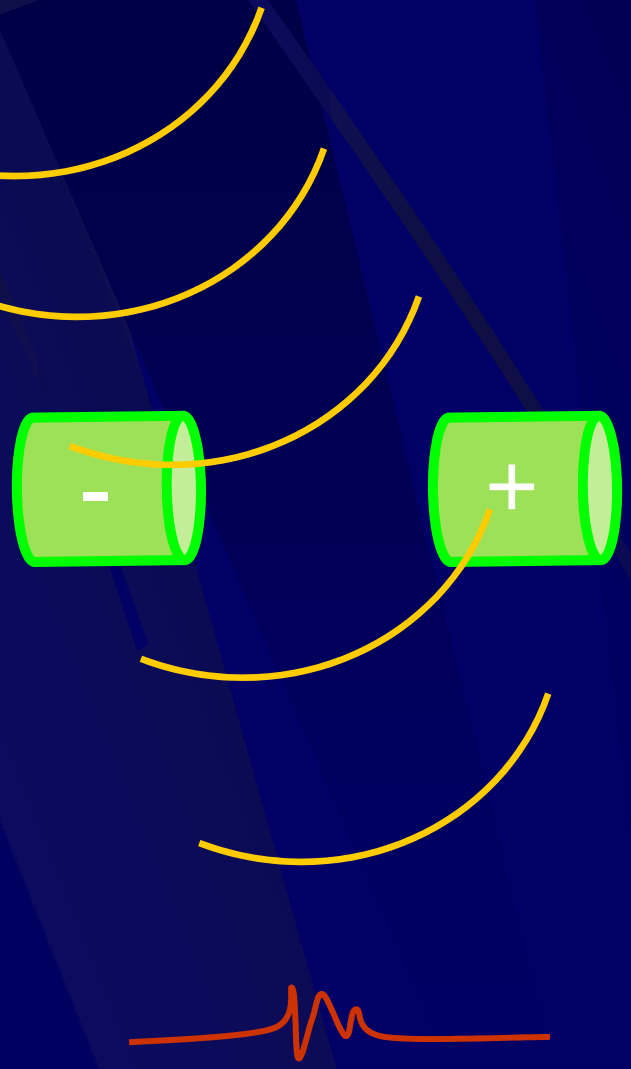

Catheter positioned near the right atrial appendage may record a far field V wave in its EGM in addition to the A wave

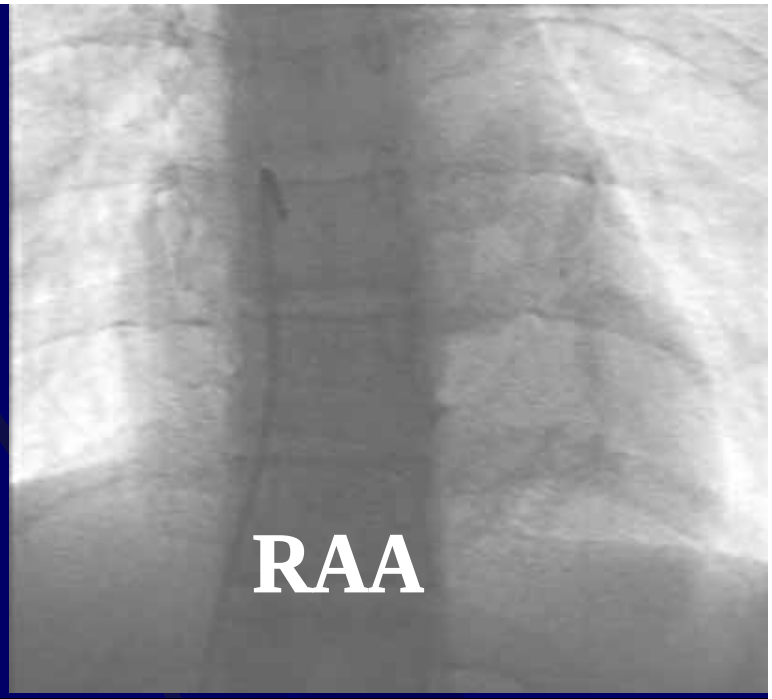



His Bundle Electrogram

- Catheter is straddled across the right atrial septum near the tricuspid valve
- Useful information on AV conduction (AV node, aberrant, pathway)
- 3 component electrogram :

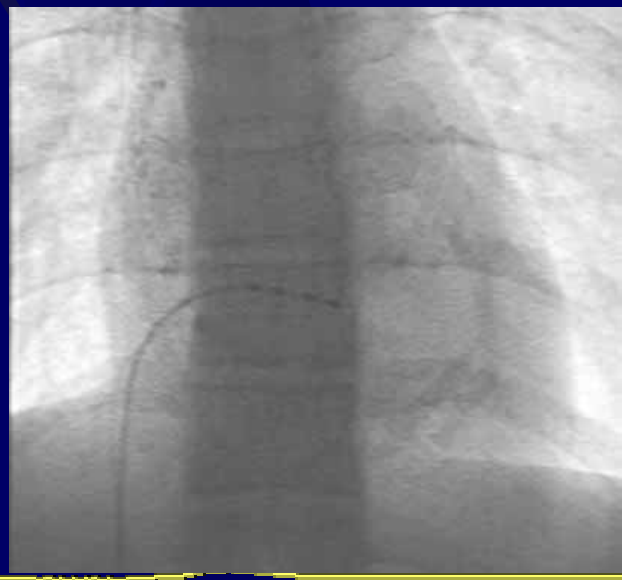

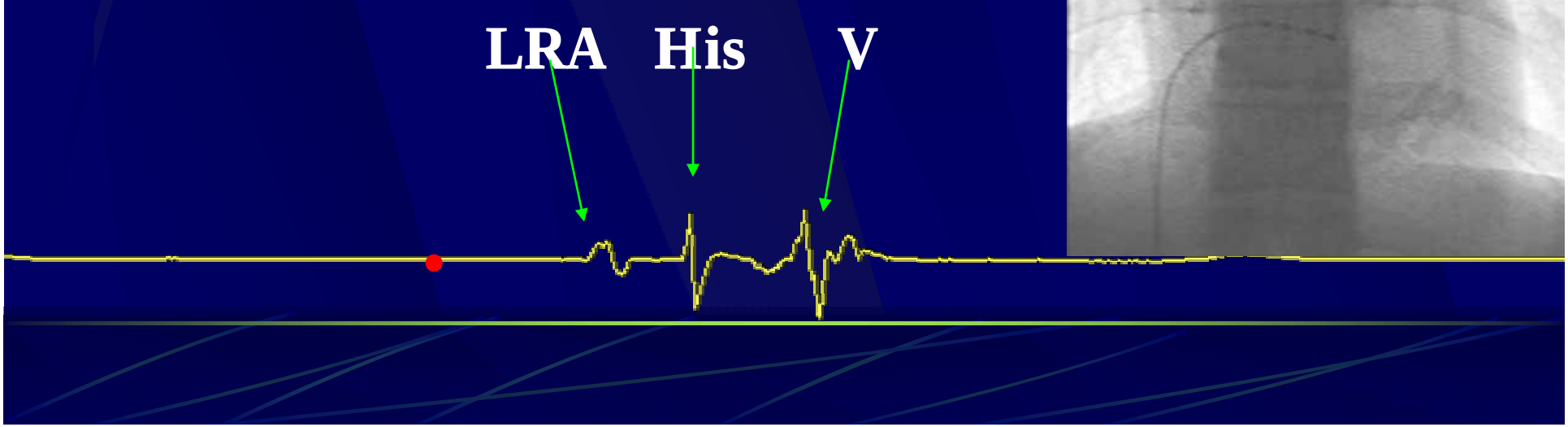

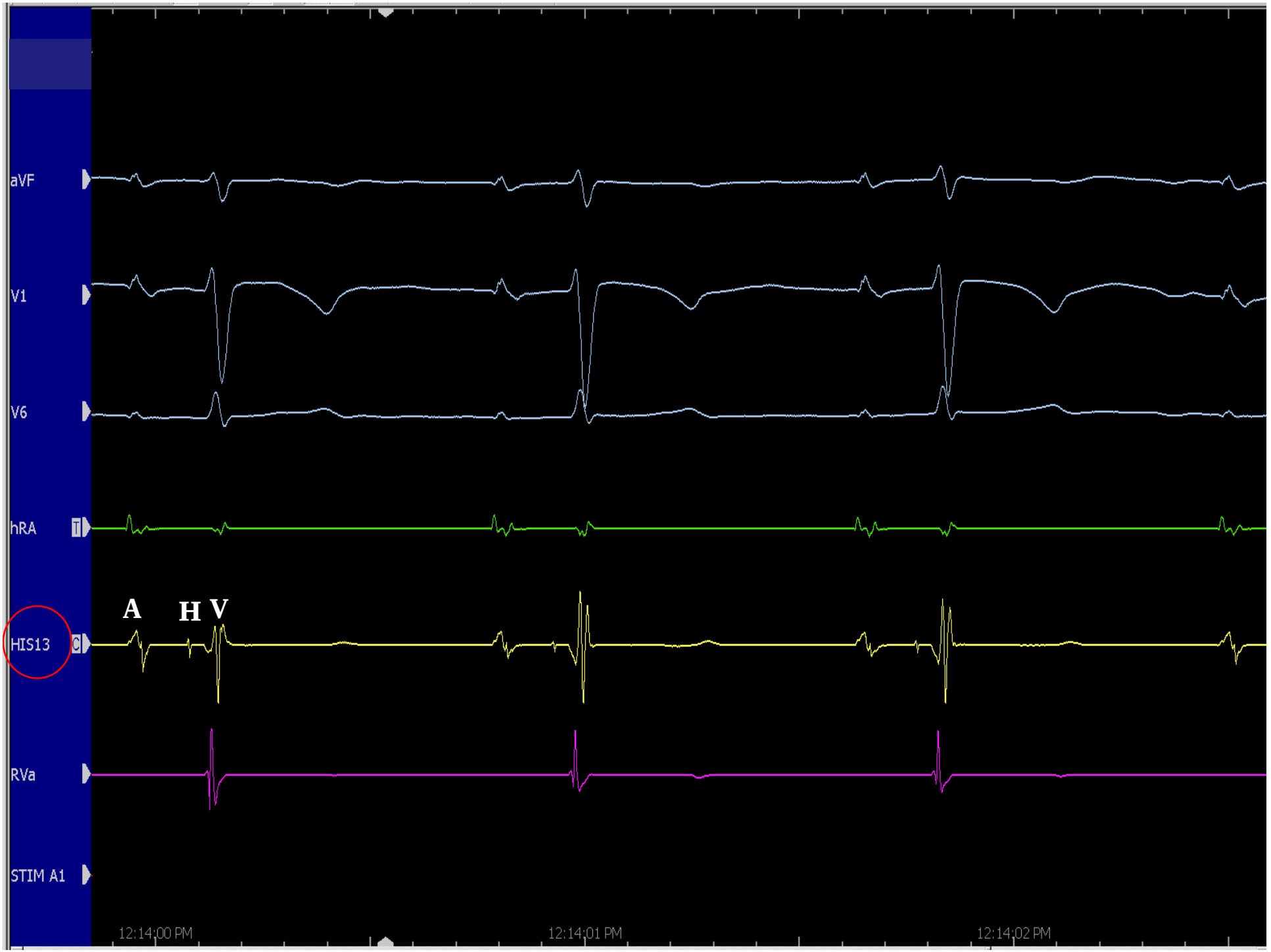
aVF
V1
V6
hRA
HIS13
A
H
V
RVa
STIM A1
12:14:00 PM
12:14:01 PM
12:14:02 PM

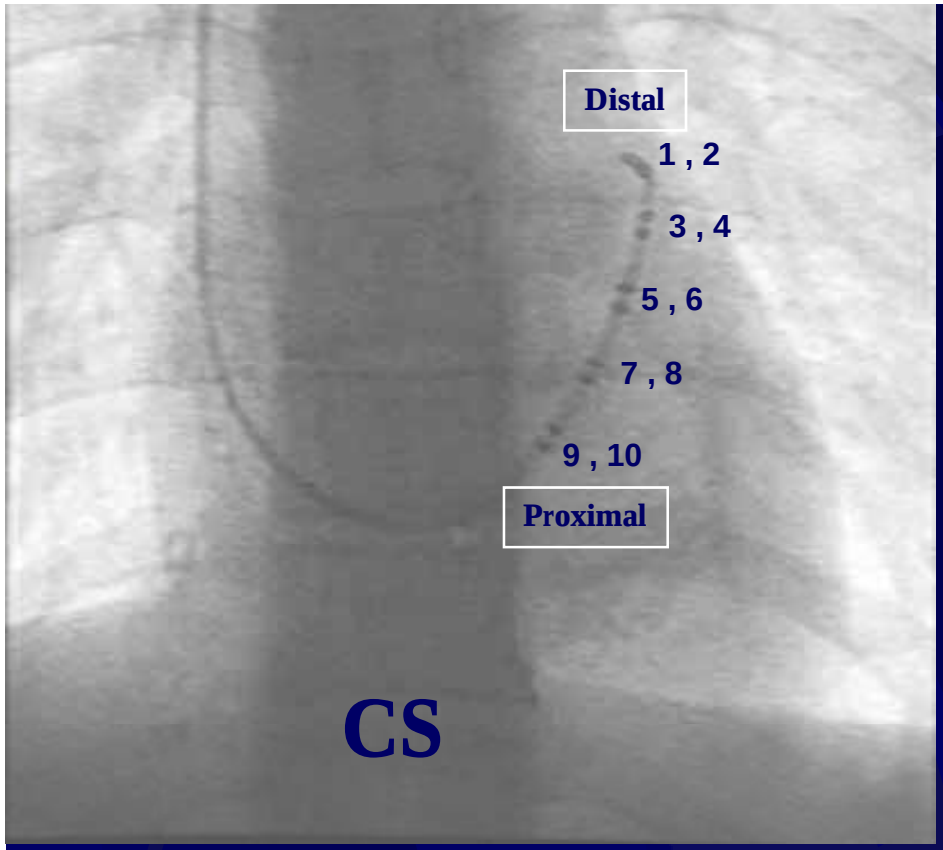

- The coronary sinus opens into the right atrium. It may be approached from the SVC or from the IVC

- Depending on the take off from the left AV groove, the CS EGM may record only A wave or both A and V waves.

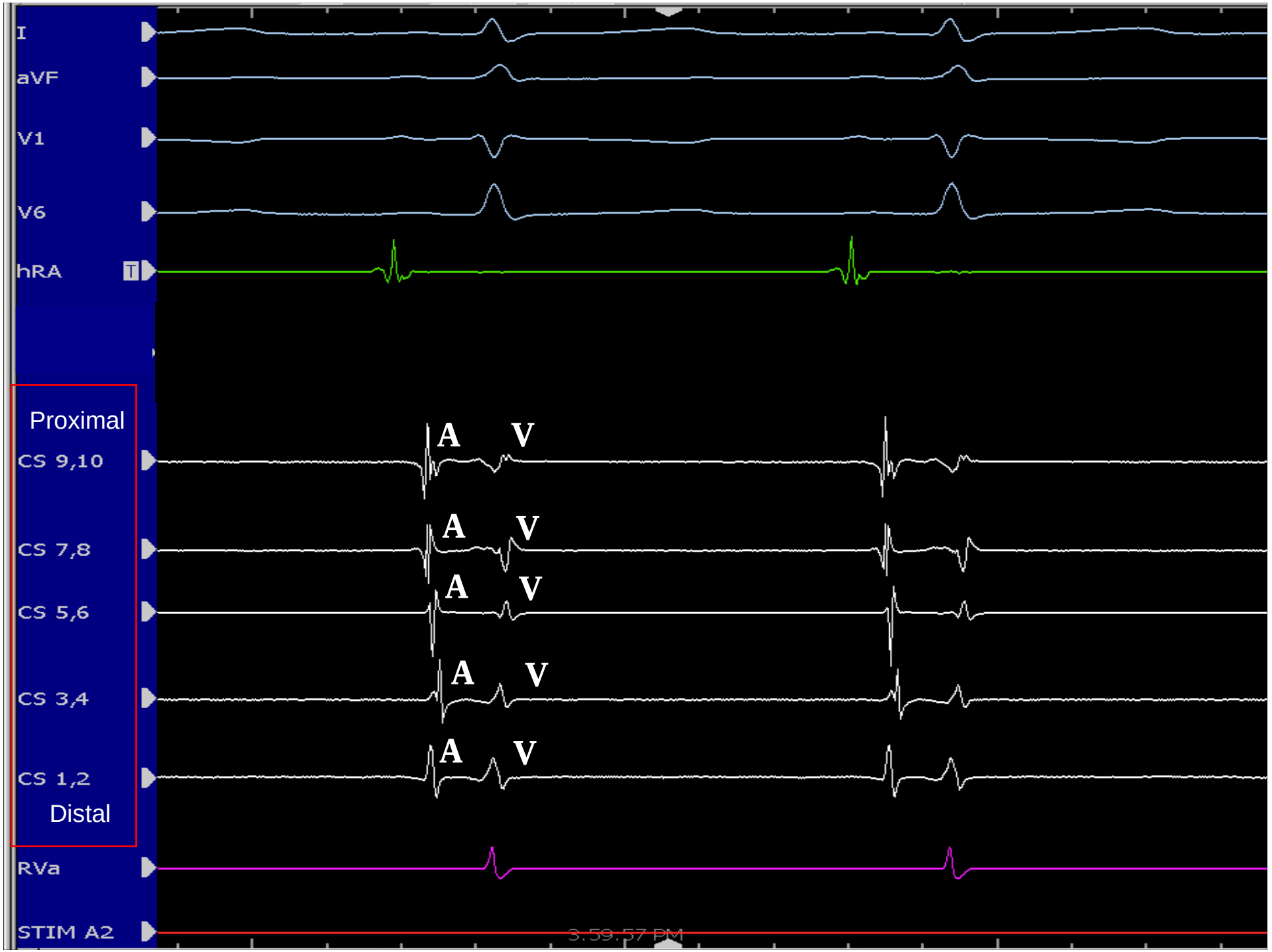
I
aVF
V1
V6
hRA
Proximal
CS 9,10
CS 7,8
CS 5,6
CS 3,4
CS 1,2
Distal
RVa
STIM A2
A
V
A
V
A
V
A
V
A
V
3:59:57 PM

Approach ECG Analysis

系统的方式, 심전도분석접근법

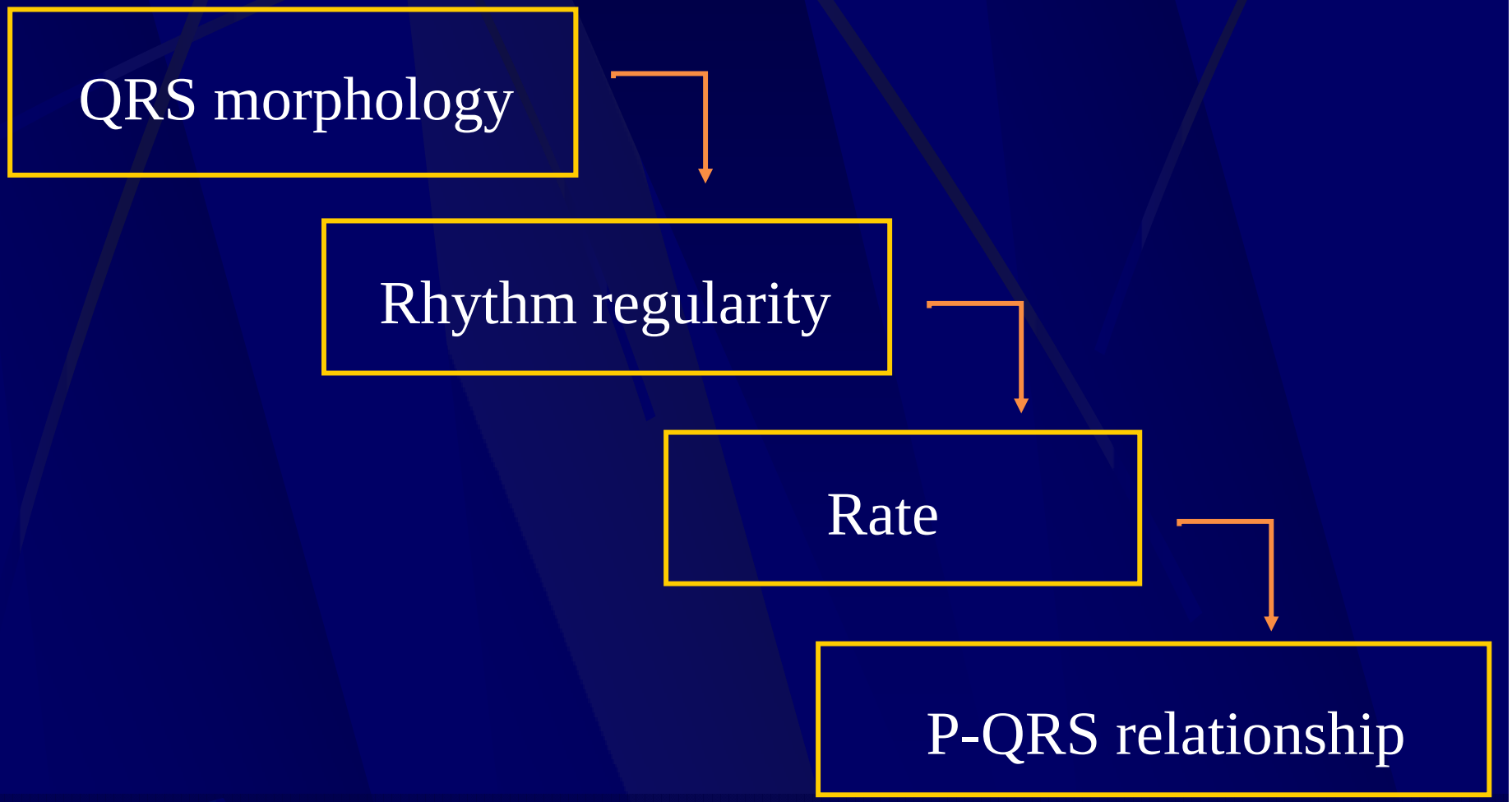

Approach EGM Analysis
심장내 전기도 분석 접근법

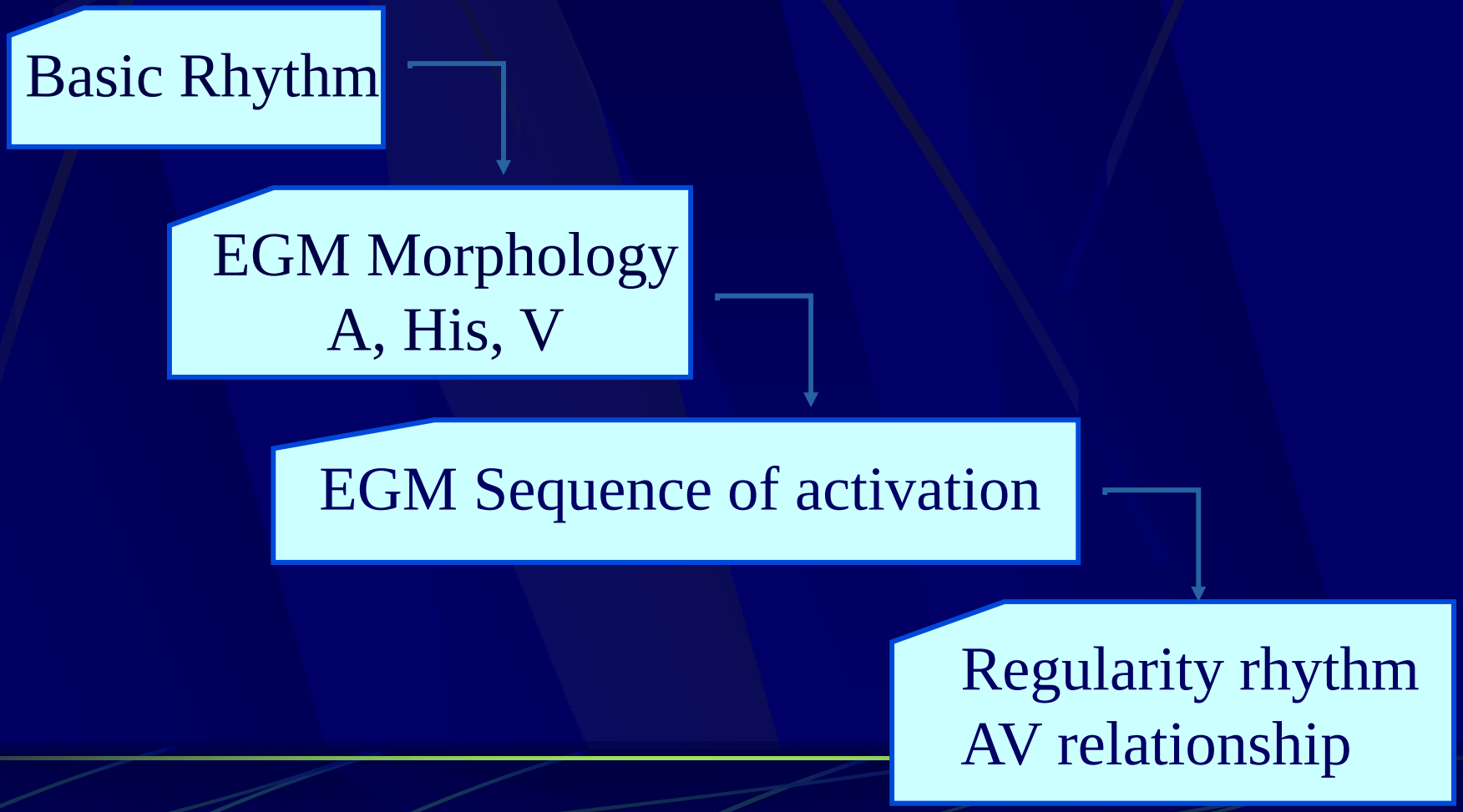

Strategies for Interpretation

Relationship

Antegrade conduction

How are the impulses from the atrium conducted to the ventricle?

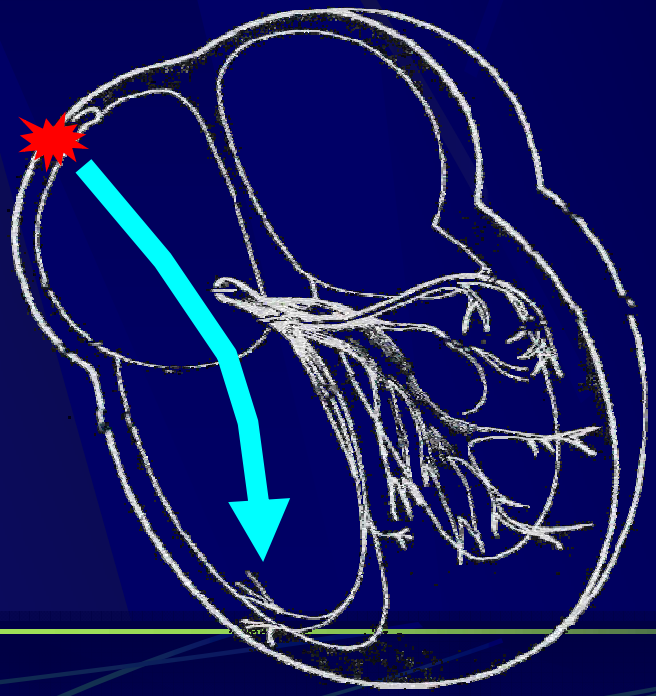

aVF
hRA
T
HIS13
C
HIS24
C
RVa
10:05:35 AM
10:05:36 AM
10:05:37 AM

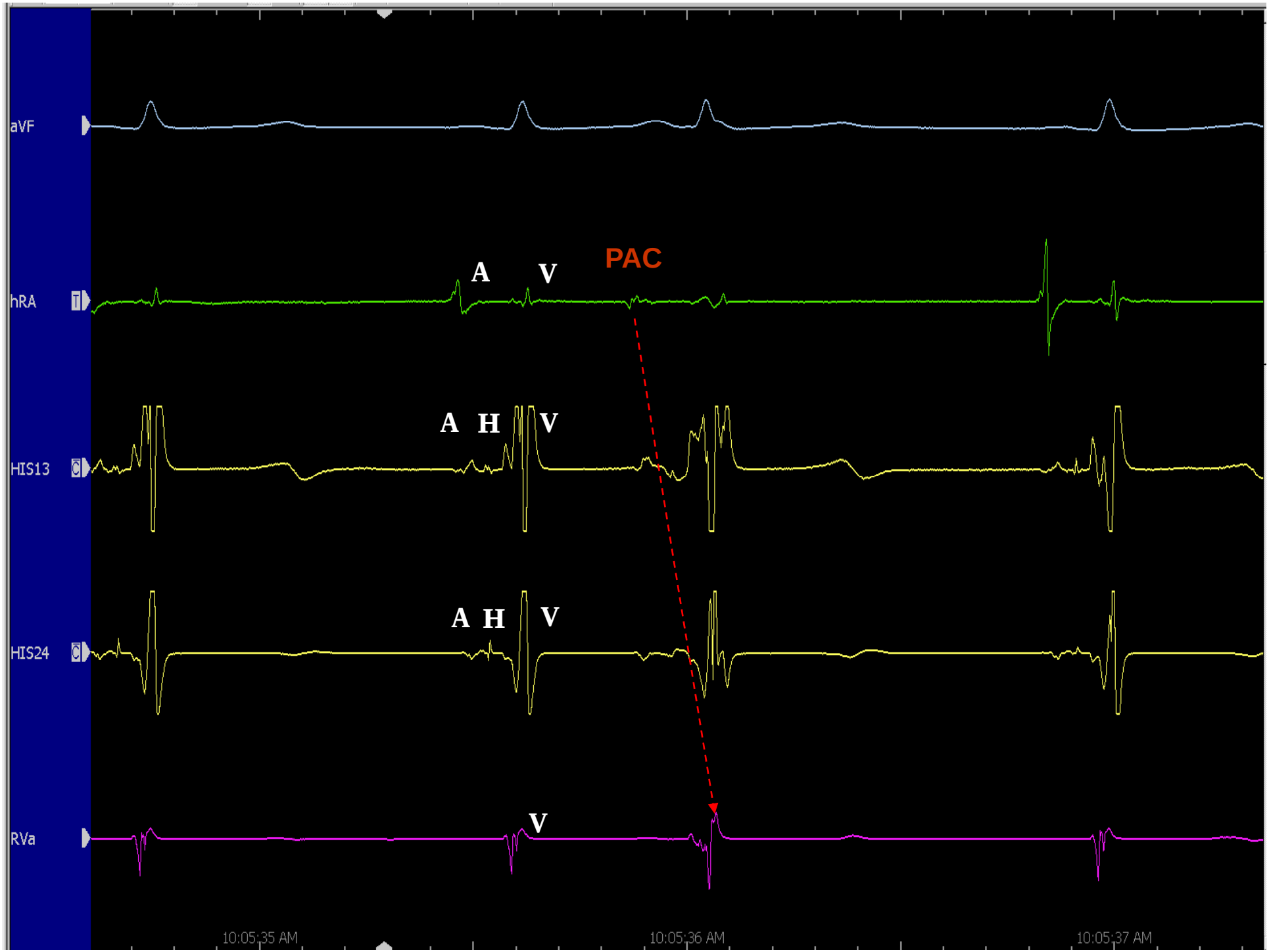
aVF
hRA
A
V
PAC
HIS13
A
H
V
HIS24
A
H
V
RVa
V
10:05:35 AM
10:05:36 AM
10:05:37 AM

Strategies for Interpretation

Relationship

Retrograde conduction

How are the impulses from the ventricle conducted to the atrium?

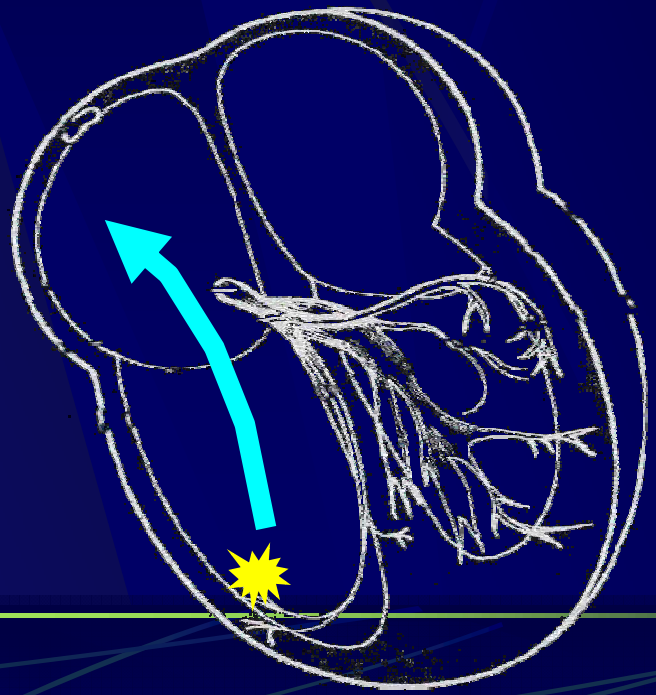

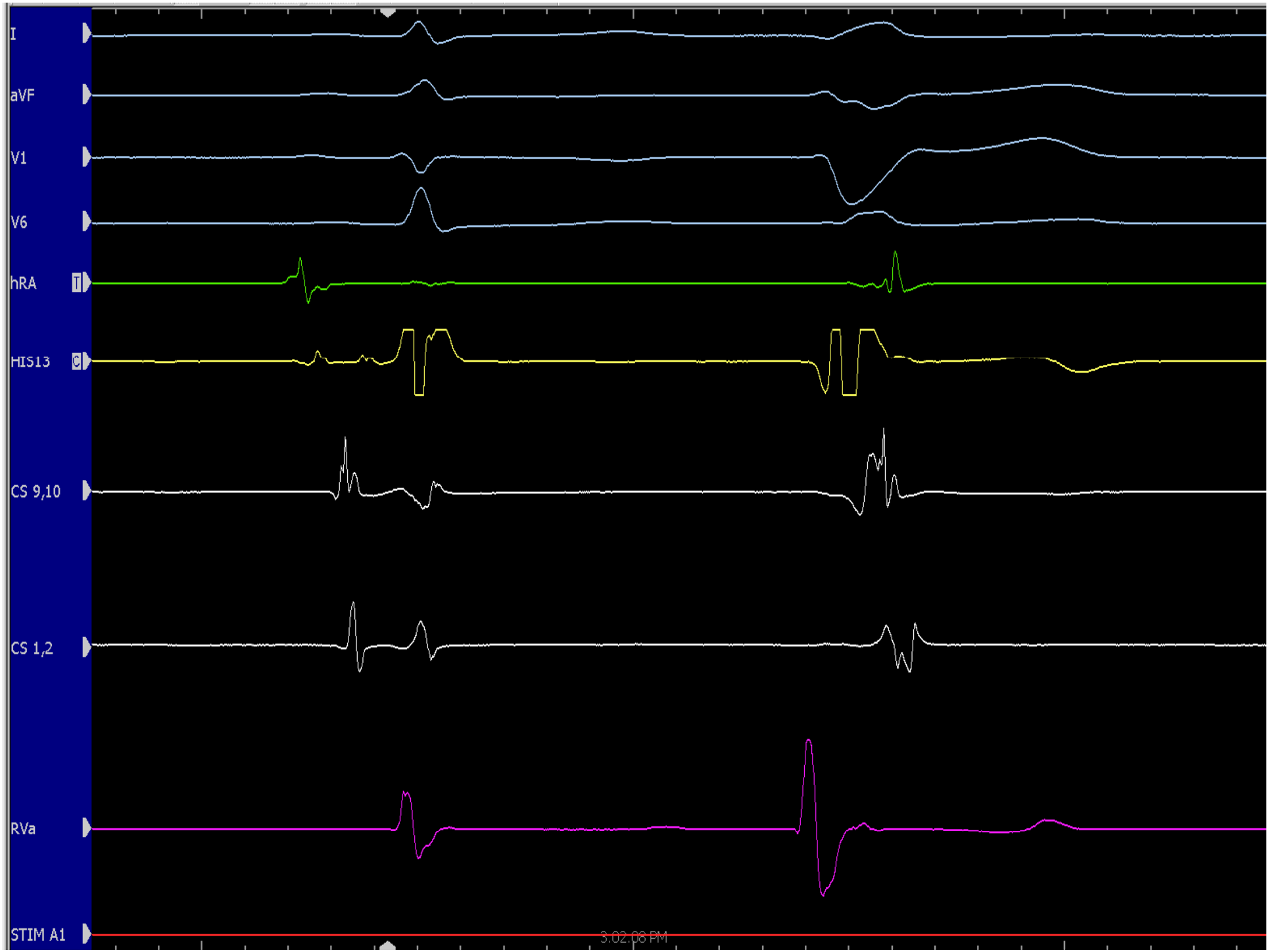
I
aVF
V1
V6
hRA
HIS13
CS 9,10
CS 1,2
RVa
STIM A1
3:02:06 PM

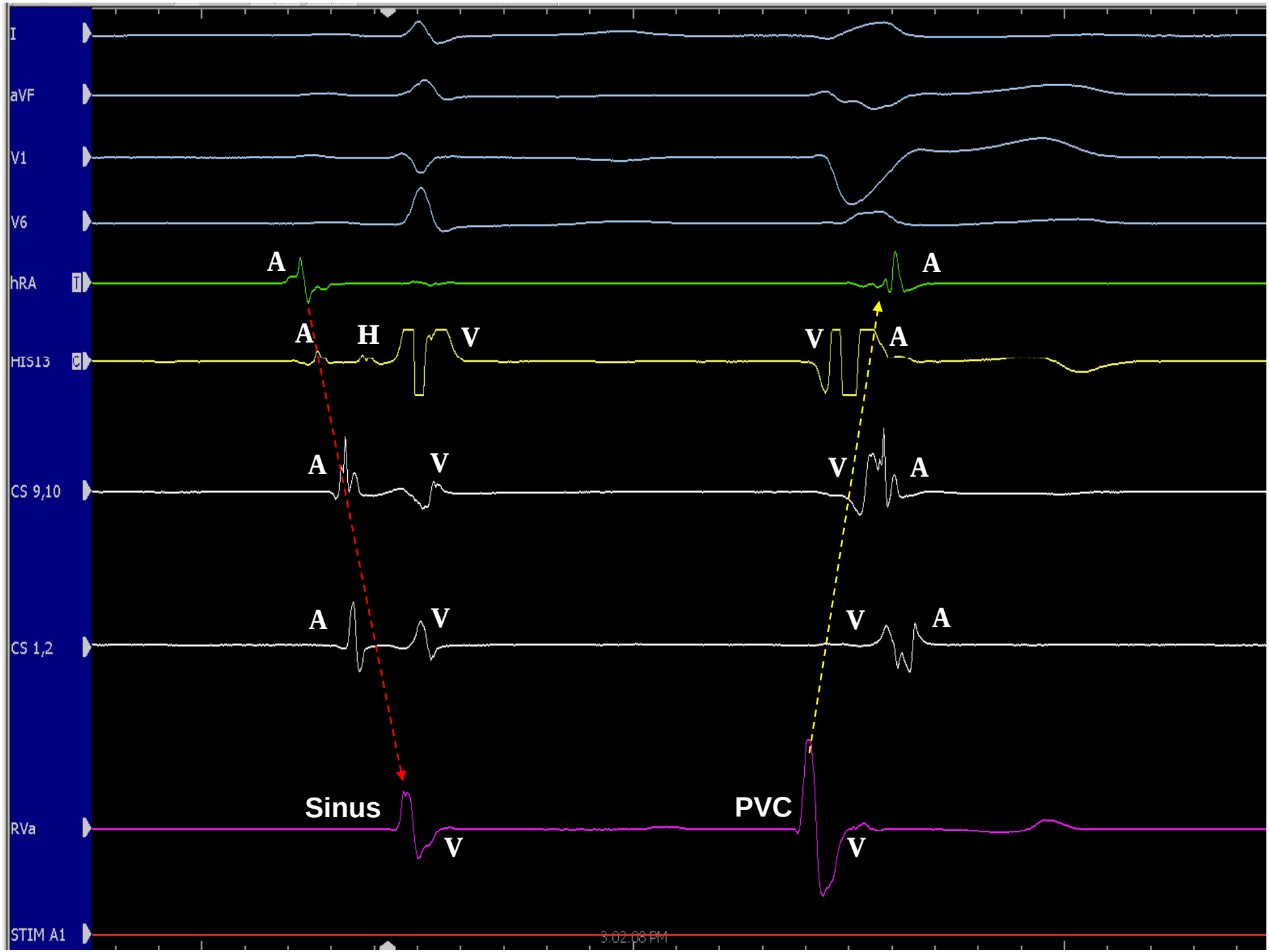
I
aVF
V1
V6
hRA
HIS13
CS 9,10
CS 1,2
RVa
STIM A1
A
H
V
Sinus
PVC
3:02:08 PM

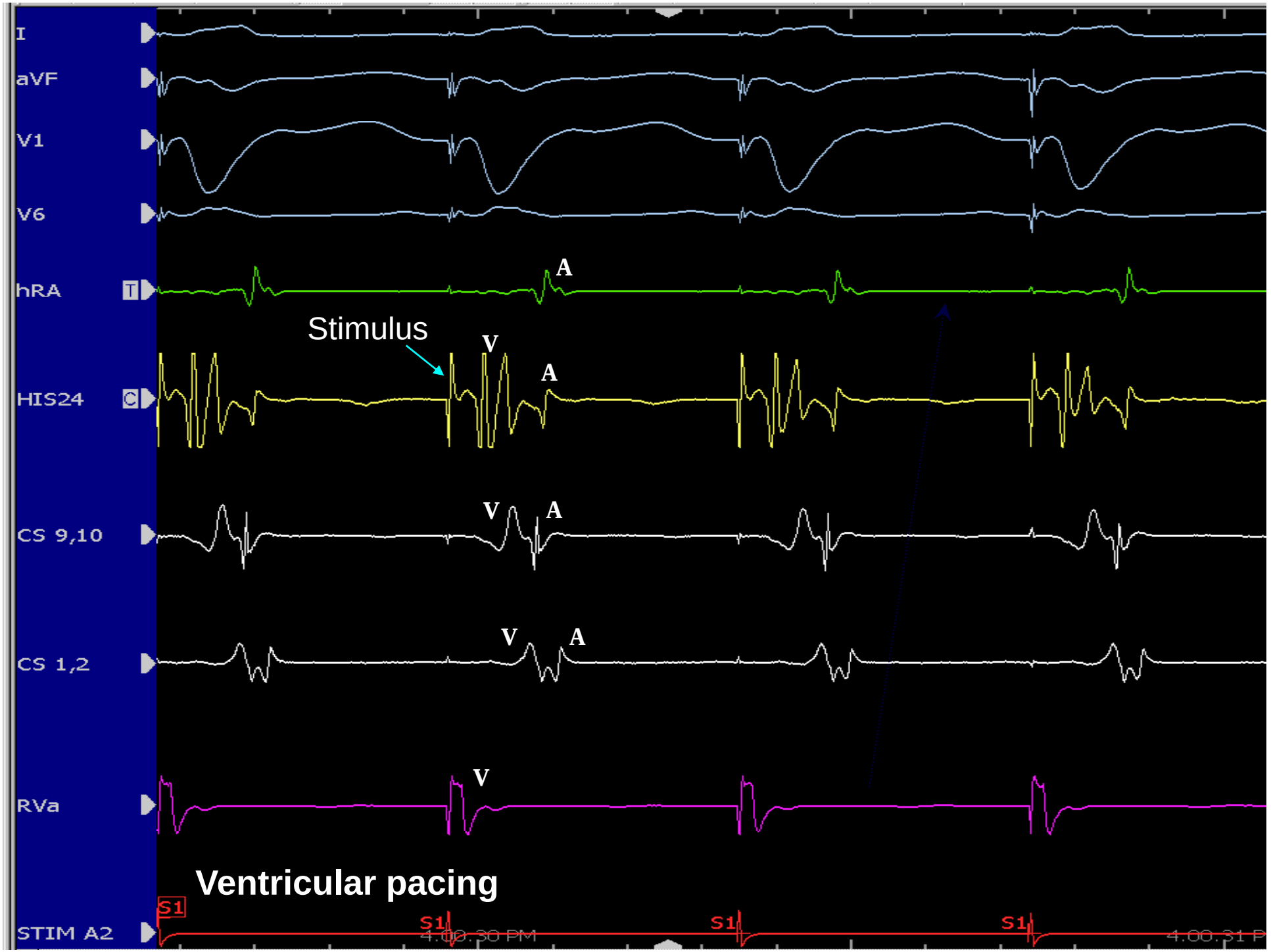
I
aVF
V1
V6
hRA
A
Stimulus
V
A
HIS24
CS 9,10
V
A
CS 1,2
V
A
RVa
V
Ventricular pacing
STIM A2
S1
S1
S1
S1
4:00:30 PM
4:00:31 P

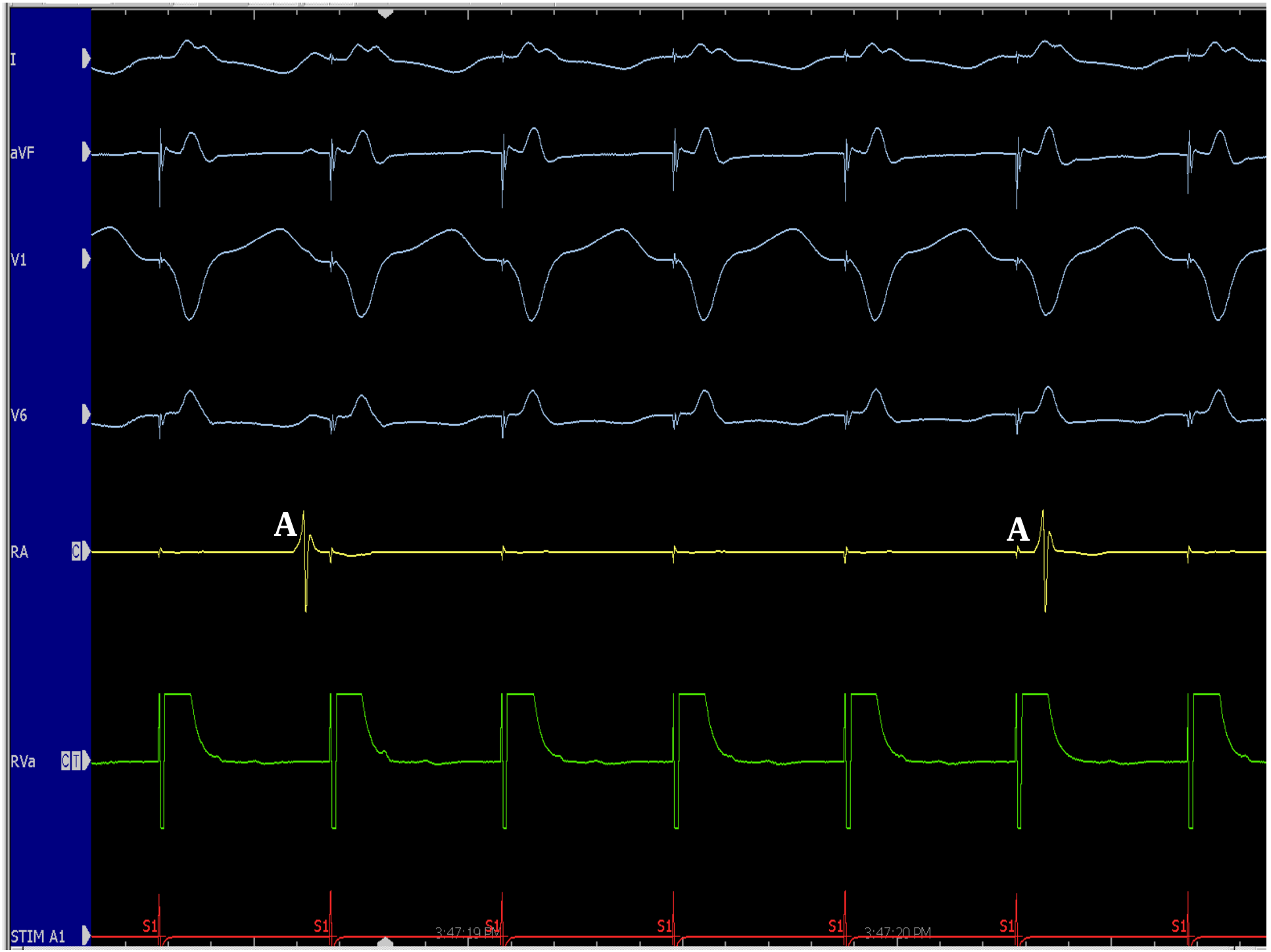
I
aVF
V1
V6
A
A
RA
C
RVa
C T
STIM A1
S1
S1
S1
S1
S1
S1
S1
3:47:19 PM
3:47:20 PM

Video 1: Baseline EGM and Ectopic Beats

Video 2: EGM Recognition During Pacing

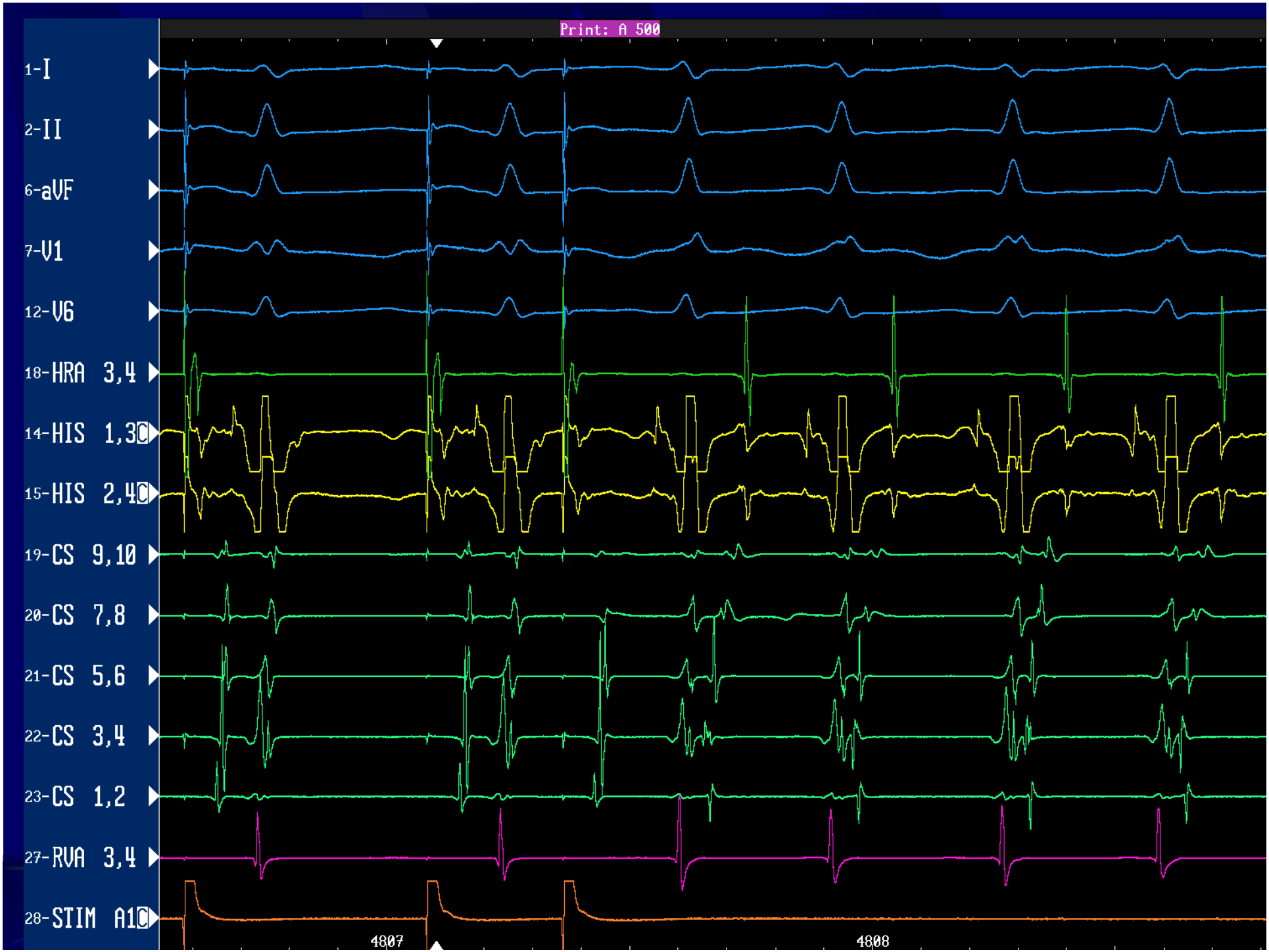
Print: A 500
1-I
2-II
6-aVF
7-V1
12-V6
18-HRA 3,4
14-HIS 1,3C
15-HIS 2,4C
19-CS 9,10
20-CS 7,8
21-CS 5,6
22-CS 3,4
23-CS 1,2
27-RVA 3,4
28-STIM A1C
4807
4808

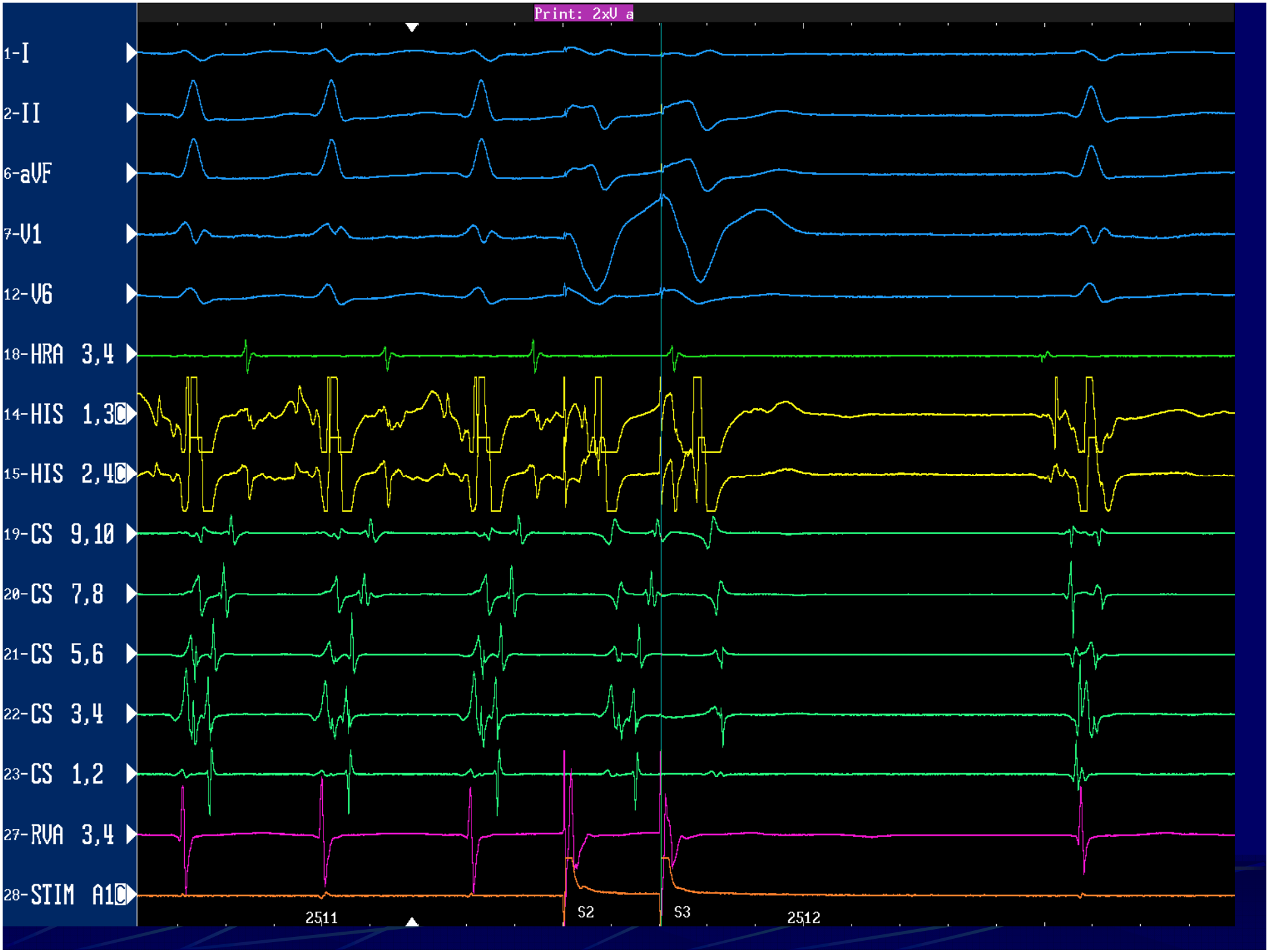
Print: 2xU a
1-I
2-II
6-aVF
7-V1
12-V6
18-HRA 3,4
14-HIS 1,3C
15-HIS 2,4C
19-CS 9,10
20-CS 7,8
21-CS 5,6
22-CS 3,4
23-CS 1,2
27-RVA 3,4
28-STIM A1C
2511
S2
S3
2512

Video 3: EGM Recognition During Mapping

Summary

- Use surface ECG and catheter position identified by fluoroscopy to help determine the electrogram waveforms.
- Use baseline IEGM to help identify electrogram waveforms during arrhythmia (Look back approach).
- Use the input/output approach to determine antegrade versus retrograde conduction.

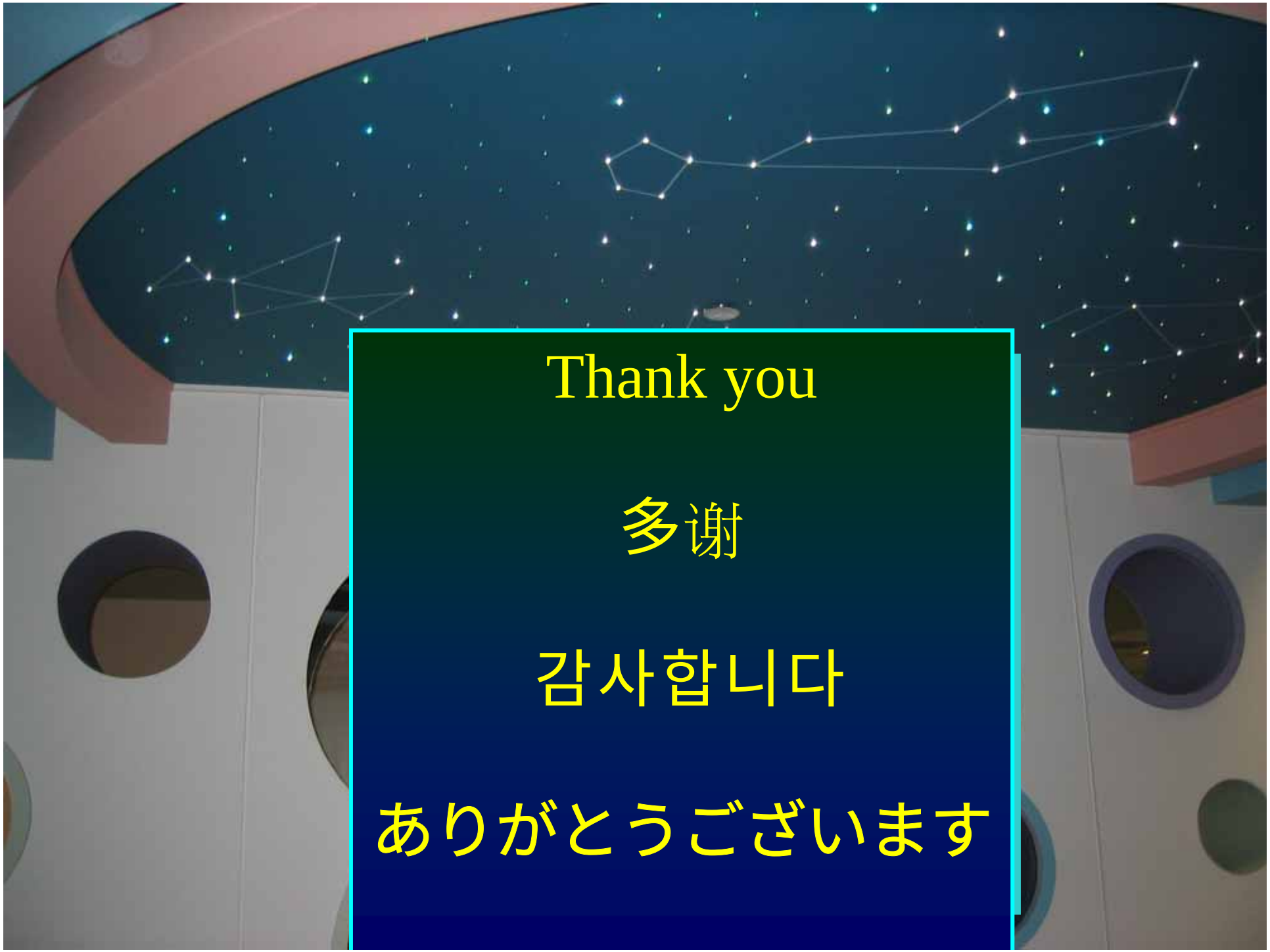
Thank you
多谢
감사합니다
ありがとうございます